



ශ්‍රී ලංකා ජාතික රෝහල
இலங்கை தேசிய வைத்தியசாலை
The National Hospital of Sri Lanka



2ND APSS Colombo Operative Spine Course


5th to 7th NOVEMBER 2017

**THE NATIONAL HOSPITAL OF SRI LANKA
COLOMBO, SRI LANKA**

SOUVENIR PROGRAMME & ABSTRACT BOOK

Central Sponsor

Medtronic



The background of the page features a collage of nature scenes. At the top, two dolphins are shown swimming in clear blue water. Below them, a large waterfall cascades down a rocky cliff. At the bottom, several elephants are seen wading through a shallow river. The text of the table of contents is overlaid on a white, rounded rectangular area that covers the left and center portions of the page.

Contents

National Organizing Committee The Sri Lanka Orthopaedic Association – Executive Committee	2
Asia Pacific Spine Society Executive Committee	3
Message from the President, Asia Pacific Spine Society	4
Message from the Deputy Director General of Health Services, The National Hospital of Sri Lanka	5
Message from the President, The Sri Lanka Orthopaedic Association	6
Message from the National Organizing Chairman	7
Faculty – International & National	8 – 10
Proposed Cases for this Operative Spine Course	11
Daily Program	12 – 14
Day 1 • 5 th November 2017 (Sunday)	
Day 2 • 6 th November 2017 (Monday)	
Day 3 • 7 th November 2017 (Tuesday)	
Abstracts	15 – 31

National Organizing Committee

Chairman
Vice Chairman
Secretary
Assistant Secretary
Treasurer
Assistant Treasurer
Editor
Patron

Dr Udai De Silva
Dr Srigrishna Paramalingam
Dr Dilshan Munidasa
Dr V Swarnakumar
Dr Harsha Mendis
Dr Parakrama Dharmaratne
Dr Rukshan Sooriyarachchi
Dr M Vasantha Perera

The Sri Lanka Orthopaedic Association Executive Committee

President
President Elect
Vice President
Immediate Past President
Secretary
Assistant Secretary
Treasurer
Editor
Assistant Editor
Councils

Dr H J Suraweera
Dr B M S Udagedera
Dr R Sooriyarachchi
Dr C Ananda Ellawala
Dr V Swarnakumar
Dr Udai De Silva
Dr Chinthaka Wijedasa
Dr K U R A Banagala
Dr Shivantha Fernandopulle
Dr M V Perera
Dr K Umapathy
Dr T G J D Munidasa
Dr R Gnanasekaram
Dr T Gobyshanger
Dr D M C L B Bopitiya
Dr Marius de Almeida
Dr J A L A Jayasinghe
Dr Yasas Jayasinghe
Dr A B S Ananda Perera
Dr G L Punchihewa
Dr Narendra Pinto
Dr S R Wijesinghe

Past Presidents

Academic Coordinator



*Asia Pacific Spine Society
Executive Committee*



Dato' Dr K S Sivananthan
MALAYSIA
President



Dr Keith Dip Kei Luk
HONG KONG
President Elect



Dr Mun Keong Kwan
MALAYSIA
Secretary



Dr Yat Wa Wong
HONG KONG
Treasurer



Dr Kuniyoshi Abumi
JAPAN
Immediate Past President



Dr Arvind Jayaswal
INDIA
Committee Member



Dr Jae Yoon Chung
KOREA
Committee Member



Dr Hee Kit Wong
SINGAPORE
Committee Member

Message from the President of the Asia Pacific Spine Society



Dear Colleagues and Friends,

It gives me the greatest pleasure to welcome you to join us at the 2nd Colombo Operative Spine Course of the Asia Pacific Spine Society (APSS) which is held at the National Hospital of Sri Lanka, Colombo from 5th – 7th November 2017. The APSS is very excited to be back again in Colombo after eight years of hiatus since the first operative course was conducted in 2009.

Since 1980, the APSS has been holding various basic and advanced operative spine courses in the Asia Pacific region, and is always eager to reach out to more spine communities in the region. This operative course will provide a constructive and conducive platform for you to enhance the principal and advanced knowledge of pathological conditions of spinal disorders and explore the latest surgical techniques of spinal surgery. With the presence of international and national faculty members, plenty of networking opportunities will be available for you to personally interact with them during the pre-operative discussion, lectures and saw bone workshops during the course. The highlight of the course is the showcase of live surgeries conducted by both our faculty members and national team, in which the surgeries will be transmitted live to the auditorium to facilitate the learning of the surgical techniques. You may look forward to the interesting discussion with the surgeons during and after their operations regarding various surgical techniques including tips and tricks to improve the positive results and to avoid complications during the surgeries.

Alongside the educational program, I encourage you to take time to immerse in Colombo's rich cultural heritage. Colombo's historical architecture that span centuries and depict many styles is proudly exhibited in their colonial buildings in the Fort area. The evenings can be greeted by soft sea breeze as you stroll along the Indian Ocean coast at Galle Face Green, or a walk in the oldest and largest urban park in Colombo, the Viharamahadevi Park (formerly Victoria Park) which is located next to the National Museum of Colombo and the Town Hall.

On behalf of the APSS, I would like to express my deepest appreciation to the society's official partner, Medtronic, for their unwavering support to our educational activities. I wish to congratulate the national organizing chairman and vice chairman, Dr Udai De Silva, Dr Srigrishna Paramalingam and SLOA Committee, for such a successful partnership in organizing this course.

I welcome you to a memorable experience in Colombo.

With warmest regards,

A handwritten signature in black ink, appearing to read 'A. Sivananthan'.

Dato' Dr K S Sivananthan
President
Asia Pacific Spine Society



Message from the Deputy Director General of Health Services, The National Hospital of Sri Lanka



It is with great pleasure and pride that I welcome you all to the 2nd APSS Colombo Operative Spine Course in the National Hospital of Sri Lanka, Colombo, Sri Lanka, organised by the Asia Pacific Spine Society (APSS) together with The Sri Lanka Orthopaedic Association.

The National Hospital of Sri Lanka is committed to provide leadership, influence and direction in the development and delivery of ideal management for patients with spinal ailments.

With The Sri Lanka Orthopaedic Association, we are in the process of establishing a national centre of excellence for spinal care. I wish and hope that this workshop along with its blend of participants would strengthen the skills and confidence in approaching spine surgeries for better clinical outcome, less pain and scarring, faster recovery time and lower risk of complications.

I pledge my fullest support to the organizing committee to make this 2nd APSS Colombo Operative Spine Course a success.



Dr Anil Jasinghe MD MSC MD MPA FCMA
Deputy Director General of Health Services
The National Hospital of Sri Lanka



Message from the President of The Sri Lanka Orthopaedic Association



As a council member of The Sri Lanka Orthopedic Association, It gives me a great pleasure to join hands with Asia Pacific Spine Society, to conduct the 2nd APSS Colombo Operative Spine Course in Sri Lanka.

On behalf of The Sri Lanka Orthopedic Association, I wish to extend a warm welcome to very eminent international faculty members from Malaysia, Hong Kong, India, Thailand, Singapore, Taiwan, Bangladesh, Turkey and Pakistan These academic faculty members are from APOA chapter member countries. I greatly applaud the efforts of APSS, the spine section of APOA for educating Sri Lankan orthopedic fraternity.

The Sri Lanka Orthopedic Association is today committed to improve the quality of care given to patients with spinal problems and we have embarked on establishing a center of excellence in Colombo, Sri Lanka for needy patients.

Considering the importance of this workshop, we have scheduled this operative course immediately after the conclusion of annual academic sessions. The annual academic sessions will be held on the 2nd, 3rd, and 4th of November 2017 at the Taj Samudra Hotel Colombo.

Finally let me thank, the national organizing chairman Dr Udai De Silva and the Vice chair Dr Srigrishna Paramalingam, Dr V Swarnakumar, the Secretary, Sri Lanka Orthopedic Association and the governing body of the APSS for their efforts in organizing this congress.

A handwritten signature in black ink, which appears to read 'Dr. H. J. Suraweera'. The signature is written in a cursive style and is positioned above a horizontal line.

Dr H J Suraweera MS FRCS
President
The Sri Lanka Orthopedic Association



Message from the National Organizing Chairman



On behalf of The Sri Lanka Orthopaedic Association (SLOA) and the course organising committee, it gives me the greatest pleasure to welcome you to the 2nd APSS Colombo Operative Spine Course from 5th to 7th November 2017 held at the National Hospital of Sri Lanka (NHSL), Colombo, Sri Lanka.

Although eight long years have elapsed since the 1st APSS Colombo Operative Spine Course which was held in 2009 under the patronage of Dr M Vasantha Perera, the pioneer spinal surgeon in Sri Lanka, Spine Surgery as a subspecialty in Orthopaedics and Neurosurgery is still in its humble beginnings and therefore we are yet to form a spine association of our own and the number of surgeons who engage in spine surgery alone is a mere handful unlike the other Asia Pacific countries.

During the 3-day course which includes pre-operative case discussions, saw bone workshops, lectures and didactics along with 8-10 live surgeries, every nanosecond of these activities will be live linked onto the auditorium in an interactive manner using the state of the art technology. The course will provide a constructive and conducive platform for the delegates to enhance the basic as well as the advanced knowledge of pathological conditions of spinal disorders which include trauma, deformity, degenerative, inflammatory/infective, congenital and neoplastic conditions. With the presence of international and national faculty members there will be plenty of opportunities for the delegates to personally interact with faculty during the course. I sincerely hope that the delegates will benefit tremendously in terms of the local and regional development of spine education in Sri Lanka by the invaluable contribution of the international faculty.

Sri Lanka is proud about its 2500 year old culture and the rich heritage and I am sure that the international faculty and the delegates will have time to spend on exploring these and the tropical beauty of the island while you are here. I sincerely hope that you will enjoy the unparalleled local hospitality and look forward to welcome you to Colombo.

Finally on behalf of my organizing committee I am very grateful for the faculty for their willingness to participate and share their knowledge and experience at the course and we are humbled by your acceptance of the invitation. I would also make this an opportunity to express my sincere appreciation of the utmost support given by the APSS Secretariat, SLOA and the organizing committee, Deputy Director General of Health Services, NHSL and other Directors of NHSL, Consultant Orthopaedic Surgeons and Neurosurgeons of NHSL & Neuro Trauma Centre and their junior associates, Consultant Anaesthetists and their junior associates, nursing and auxiliary staff of Neuro Trauma Spinal Ward, orthopaedic wards, orthopaedic operating theatre, OTT and intensive care units, the sponsors and the audiovisual team without whose support it would not have been possible to organize a live operative course of this magnitude, splendour and grandeur.

With warmest regards



Dr Uday De Silva MS FRCSEd FCSSl

Assistant Secretary, The Sri Lanka Orthopaedic Association

National Organizing Chairman, 2nd APSS Colombo Operative Spine Course 2017

Faculty

– International & National



DATO' K S SIVANANTHAN
Orthopaedics & Traumatology Department
Hospital Fatimah, Ipoh
Malaysia



KEITH DIP KEI LUK
Department of Orthopaedics and Traumatology
The University of Hong Kong
Queen Mary Hospital
Hong Kong



MUN KEONG KWAN
Spine Unit, University of Malaya, Kuala Lumpur
University Malaya Medical Centre, Kuala Lumpur
Malaysia



YAT WA WONG
Department of Orthopaedics and Traumatology
The University of Hong Kong
Queen Mary Hospital
Hong Kong



ARVIND JAYASWAL
Department of Spine Surgery
Primus Super Speciality Hospital
New Delhi
India



JAE-YOON CHUNG
Chonnam University Medical School
Gwangju Hyundae Hospital
Korea



Faculty
– International & National [continued]



WARAT TASSANAWIPAS
Department of Orthopaedics
Phramongkutklao Army Hospital
Thailand



GABRIEL LIU
Department of Orthopaedic Surgery
National University Hospital
Singapore



SHU-HUA YANG
Department of Orthopedics
National Taiwan Univeristy Hospital
Taiwan



MUHAMMAD TARIQ SOHAIL
Doctors Hospital and Medical Center
Lahore, Punjab
Pakistan



MD SHAH ALAM
Department of Spine & Orthopaedic Surgery
National Institute of Traumatology &
Orthopaedic Rehabilitation
Bangladesh



MEHMET AYDOGAN
Bosphorus Spine Center
Turkey

Faculty

– International & National [continued]



CHRIS YIN WEI CHAN

Spine Unit, University of Malaya, Kuala Lumpur
University Malaya Medical Centre, Kuala Lumpur
Malaysia



PANKAJ KANDWAL

Department of Orthopaedics
All India Institute of Medical Sciences (AIIMS)
Rishikesh
India



UDAI DE SILVA

Department of Orthopaedics
Provincial General Hospital, Badulla
Sri Lanka



M VASANTHA PERERA

Nawaloka Hospitals Pvt Ltd & Neville
Fernando Teaching Hospital, Colombo
Sri Lanka



Proposed Cases for this Operative Spine Course

1. Cervical Spine
 - a. Anterior Cervical i.e. ACDF or ACCF
 - b. Anterior Cervical i.e. Arthroplasty
 - c. Posterior Cervical Fixation i.e. Lateral Mass or Pedicle Screw Fusion
 - d. Posterior Cervical Decompression i.e. Laminoplasty
 - e. Posterior Cervical C1/2 Fusion
 - f. Posterior Occipitocervical Fusion

2. Coronal Deformity Correction
 - a. Adolescent Idiopathic Scoliosis i.e. Posterior Instrumented Spinal Fusion

3. Sagittal Deformity Correction
 - a. Ankylosing spondylitis
 - b. Scheuermann kyphosis
 - c. Neglected traumatic fracture
 - d. TB spine kyphosis

4. Spinal Instability +/- Neurological Deficit for Stabilization +/- Decompression
 - a. Traumatic acute fracture
 - b. Spinal infection
 - c. Spinal metastases

5. Lumbar Spinal Stenosis (LSS)
 - a. Decompression alone i.e medial facetectomy, laminectomy or internal laminolasty, discectomy for HNP
 - b. Decompression and fusion i.e. Open TLIF, MIS TLIF or DLIF

*** The final operative list/cases will be decided on 5th November 2017 during the pre-operative assessment. 8 – 10 cases will be selected from the above list for live surgery telecast during the entire 3-day course.**

0830 – 0900

REGISTRATION OF PARTICIPANTS

0900 – 1200

Pre-Operative Cases Discussion

1400 – 1530

Saw Bones Workshop 1

Thoracic Pedicle Screw, Lumbar Pedicle Screw, S1 Screw, Iliac Screw and S2AI Screw Fixation

Warat Tassanawipas, Shu-Hua Yang

1530 – 1700

Saw Bones Workshop 2

Posterior Instrumentation of Cervical Spine i.e. C1/C2 Fixation, Lateral Mass and Cervical Pedicle Screw Fixation / Anterior Cervical Discectomy Fusion

Dato' K S Sivananthan, Yat Wa Wong

1900

Faculty Dinner

(Lunch & Refreshments at Cafeteria, 7th Floor, Neuro Trauma Centre)

DAILY
PROGRAMME

DAY 2

6th November 2017 (Monday)

Venue: Neuro Trauma Auditorium, 8th Floor, Neuro Trauma Centre

0830 – 0900

OPENING CONFERENCE

- Lighting of Traditional Oil Lamp & National Anthem
- The SLOA President's Welcome Speech
H J Suraweera
- The APSS President's Welcome Speech
Dato' K S Sivananthan
- Address by Deputy Director General, National Hospital of Sri Lanka
Anil Jasinghe
- Vote of Thanks from the National Organizing Chairman
Udai De Silva

0900 – 0915

MIS in Spinal Trauma *[page 16-17]*

Warat Tassanawipas

0915 – 0930

Cervical Myelopathy *[page 18-19]*

Keith Dip Kei Luk

0930 – 0945

Anterior Cervical Discectomy & Fusion (ACDF) *[page 20]*

Md Shah Alam

0945 – 1000

Surgical Management of O-C1-C2 Injuries *[page 21]*

Mehmet Aydogan

1000 – 1015

TLIF with Cortical Pedicular Screw Fixation *[page 22]*

Dato' K S Sivananthan

1015 – 1030

Mini-ALIF with Transverse Para-Rectal Incision *[page 23]*

Jae-Yoon Chung

1030 – 1045

Lumbar Instability *[page 24]*

Gabriel Liu

0900 – 1700

Live Surgery

Venue: OTO, 1st Floor, Accident & Orthopaedic Service

- Operation Theatre 1
- Operation Theatre 2
- Operation Theatre 3

1930

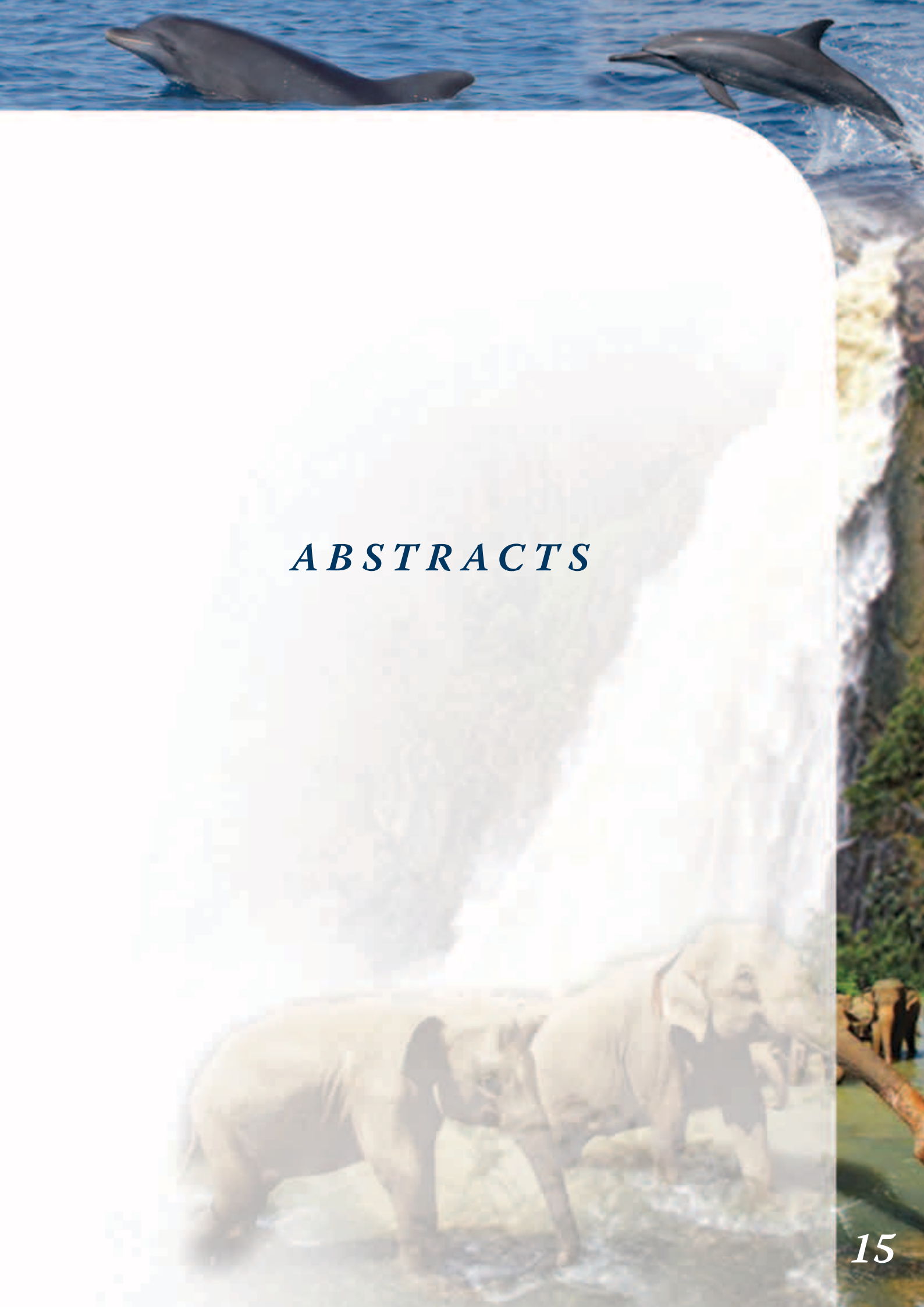Course Dinner

Venue: Light House Cafe, Colombo 1

(Lunch & Refreshments at Cafeteria, 7th Floor, Neuro Trauma Centre)

0830 – 0845	DISCUSSION AND EVALUATION POST-OP CASES DONE ON DAY 2
0845 – 0900	Selection of Fusion Levels in Corrective Surgery for Adolescent Idiopathic Scoliosis [page 25] <i>Shu-Hua Yang</i>
0900 – 0915	Non-Fusion Growth Modulation for the Treatment of Juvenile Idiopathic Scoliosis [page 26-27] <i>Arvind Jayaswal</i>
0915 – 0930	Adolescent Idiopathic Scoliosis – Evaluation and Surgical Strategies [page 28] <i>Udai De Silva</i>
0930 – 0945	Congenital Scoliosis – Management Principles [page 29] <i>Yat Wa Wong</i>
0945 – 1000	Management of Post-TB Kyphosis [page 30] <i>Muhammad Tariq Sohail</i>
1000 – 1015	Management of Spinal Metastasis [page 31] <i>Chris Yin Wei Chan</i>
0830 – 1700	Live Surgery <i>Venue: OTO, 1st Floor, Accident & Orthopaedic Service</i> <ul style="list-style-type: none">▪ Operation Theatre 1▪ Operation Theatre 2▪ Operation Theatre 3
1700	CLOSING AND CERTIFICATE PRESENTATION

(Lunch & Refreshments at Cafeteria, 7th Floor, Neuro Trauma Centre)



ABSTRACTS

MIS IN SPINAL TRAUMA

Warat Tassanawipas

Orthopaedics, Phramongkutklao Hospital, Bangkok, Thailand

Management strategies for spinal injuries depend on the type and severity of the injury by obtaining and maintaining spinal stability and optimising neurological status.

An optimal treatment both non – operative treatment with orthoses and casting or operative treatment should provide the potential good outcomes by reducing the detrimental effects of injury, reducing pain early mobility and good quality of life.

Conventional open techniques are association with significant morbidity due to increased infection rates and high blood loss, muscle denervation, ischemia, fibrosis and atrophy which decreased extensor strength and endurance as well as increase morbidity postoperative pain.

The goal of MIS procedures is to achieve the same good outcomes and results as conventional open technique while limiting the morbidity by providing the spinal stability, restore alignment and return of function as soon as possible.

MIS approaches are associated with reduced intraoperative blood loss, improvement of post – operative pain, enhance early mobilization and short hospital stay. However there are many barriers such as high learning curve, high – quality of equipment and instruments and imaging technologies like navigators and robot system.

It must be emphasized that the MIS techniques for spinal trauma must base on reduction and realignment and adequate decompression.

Spinal stability by anterior column support and restoration of the posterior element and fusion is mandatory.

The common MIS techniques nowadays are shown in table I

TABLE 1: CURRENT MIS TECHNIQUES USED IN TL TRAUMA¹

MIS TECHNIQUE (S)	INDICATIONS
Anterior endoscopic decompression and stabilization	Anterior decompression
	Anterior column reconstruction
Posterior percutaneous segmental pedicle screw fixation	Restoration of posterior tension band
	Indirect augmentation of anterior column
	Augmentation of anterior fixation
Percutaneous vertebral body balloon-assisted endplate reduction and augmentation	Substitution for when direct anterior fixation is not feasible
	Endplate reduction and vertebral height restoration Augmentation of anterior column
Temporary percutaneous posterior fixation	Temporary stabilization to facilitate mobilization or prevention of secondary injury in an unstable injury when definitive fixation is unsafe
Combinations of the above	

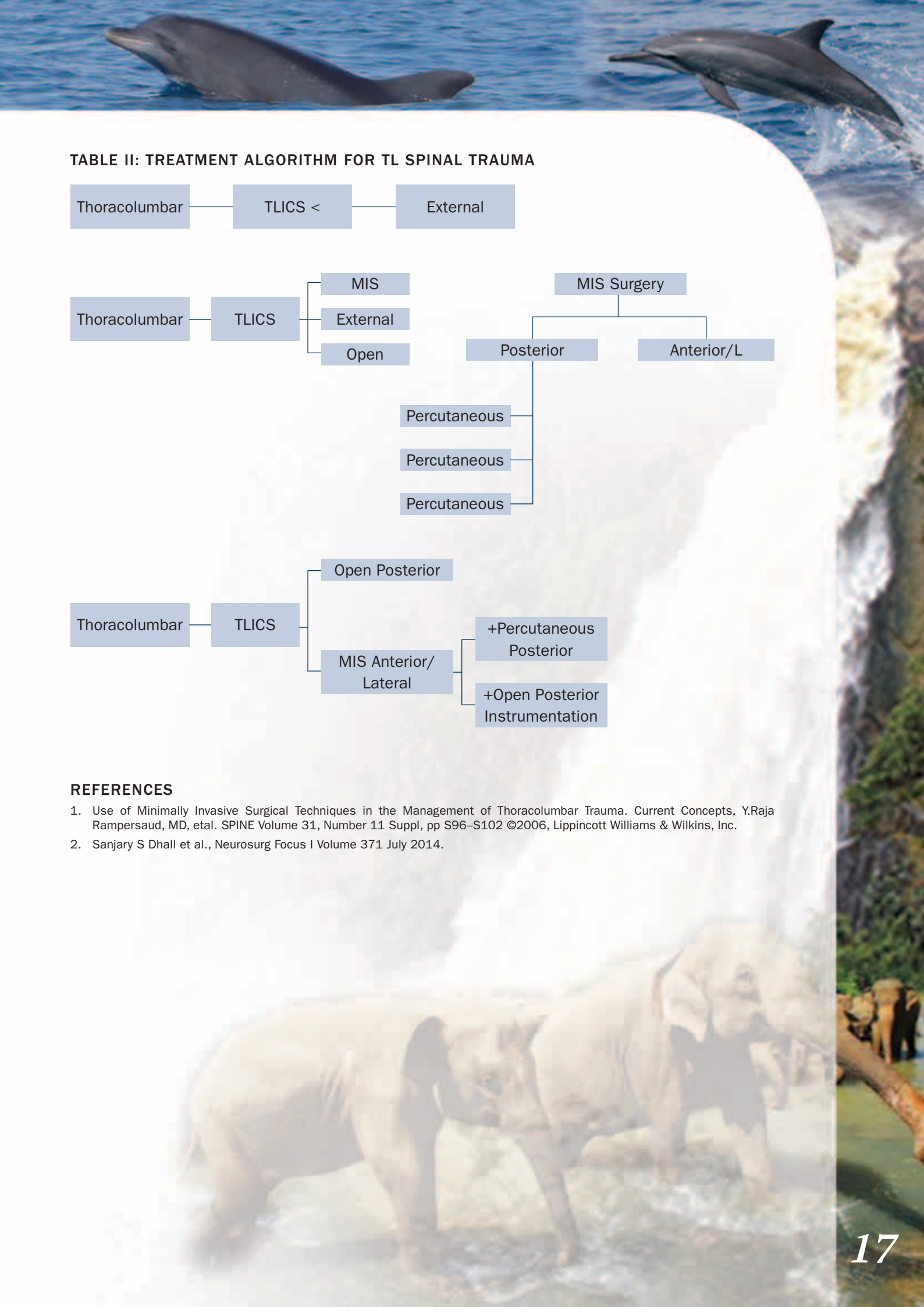
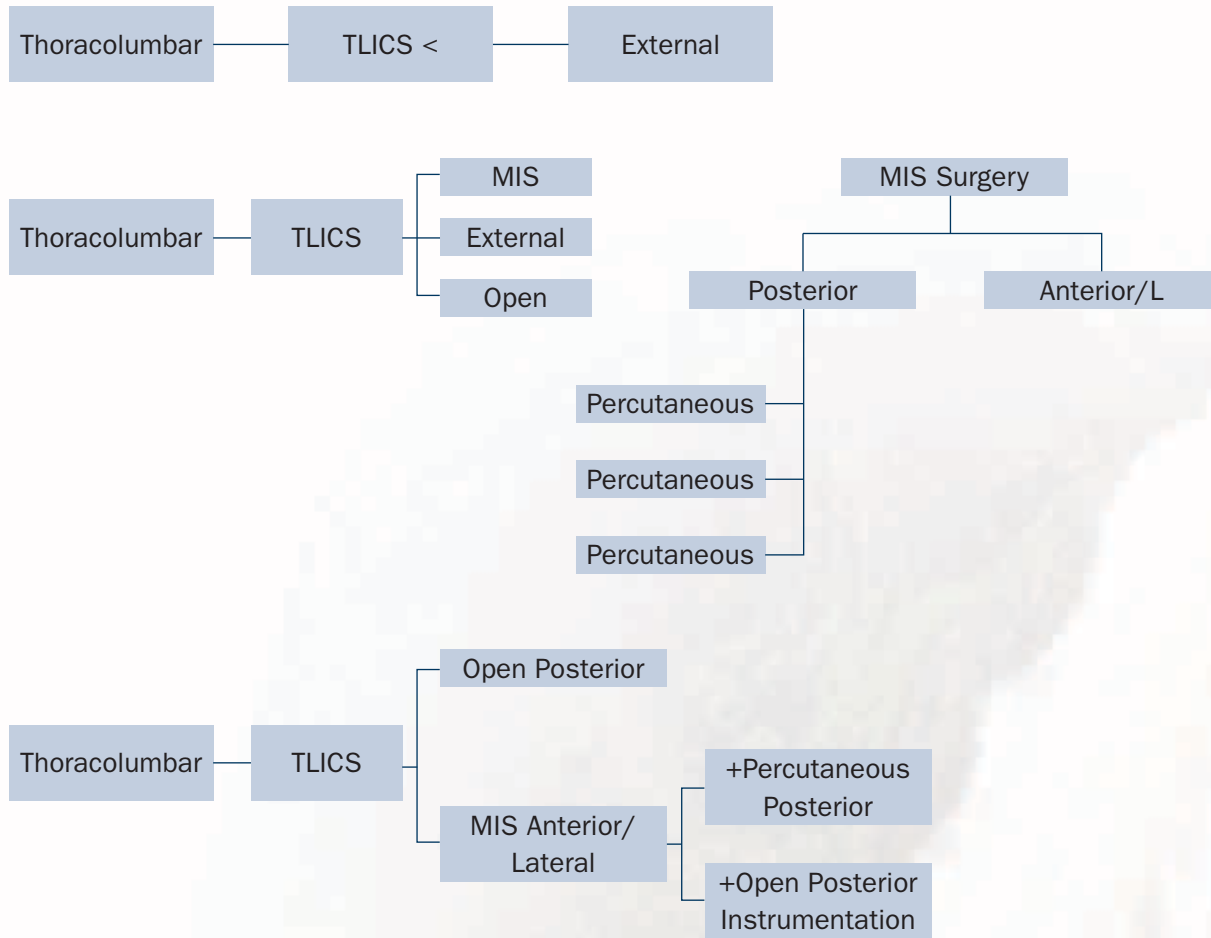


TABLE II: TREATMENT ALGORITHM FOR TL SPINAL TRAUMA



REFERENCES

1. Use of Minimally Invasive Surgical Techniques in the Management of Thoracolumbar Trauma. Current Concepts, Y.Raja Rampersaud, MD, et al. SPINE Volume 31, Number 11 Suppl, pp S96–S102 ©2006, Lippincott Williams & Wilkins, Inc.
2. Sanjary S Dhall et al., Neurosurg Focus I Volume 371 July 2014.

CERVICAL MYELOPATHY

Keith D K Luk

Tam Sai Kit Professor in Spine Surgery, Chair Professor,
Department of Orthopedic & Traumatology, University of Hong Kong

COMMON CAUSES OF CERVICAL MYELOPATHY

1. Congenital spinal stenosis (<12mm)
2. Cervical spondylosis (CSM)
3. Ossification of posterior longitudinal ligament (OPLL)
4. Cervical kyphosis
5. Impaired spinal cord blood supply

NATURAL HISTORY OF CERVICAL SPONDYLOTIC MYELOPATHY

- | | |
|-----|----------------------|
| 75% | episodic progression |
| 20% | steady progression |
| 5% | rapid deterioration |

CERVICAL SPONDYLOTIC MYELOPATHY

1. Weakness and muscle wasting
2. Loss of hand dexterity
3. Numbness and paraesthesia
4. Spasticity
5. Loss of balance

Clark 1956

CERVICAL SPONDYLOTIC MYELOPATHY

1. 10-seconds test
2. Finger escape sign
3. Hoffmann reflex

PROGNOSTICATING FACTOR

transverse area of cord < 30 mm²

CONTRIBUTING FACTORS

- chronicity of disease
- age at surgery
- multiplicity of involvement



INDICATIONS FOR SURGERY

1. Progressive neurologic deficit
2. Impaired ADL (JOA score)
3. Compatible imaging findings

INDICATIONS FOR POSTERIOR SURGERY

1. Central canal stenosis
2. No pre-existing instability
3. Normal sagittal curvature
4. Multiple level disease (>3 levels)
 - i. CSM
 - ii. continuous, mixed OPLL

CHOICES OF POSTERIOR DECOMPRESSION

1. Laminectomy
2. Expansive laminoplasty
 - i. Z-plasty (Hattori)
 - ii. Open door (Hirabayashi, Itoh)
 - iii. Double door (Kurokawa)

INDICATIONS FOR ANTERIOR SURGERY

- Pre-existing cervical kyphosis
- Pre-existing instability
- Segmental compression (<3 levels)

EARLIEST SYMPTOM OF RECOVERY

- Relieve of “tightness” over body
- Improve finger dexterity

ANTERIOR CERVICAL DISCECTOMY & FUSION (ACDF)

*¹Md Shah Alam, ¹Md Rezaul Karim, ¹Anisur Rahman, ¹Sharif Ahmed Jonayed,
²Hasan Khalid Md Munir, ¹Abul Kalam Azad, ¹Abdullah Al Mamun,
¹ Sarwar Jahan, ¹Shubhendu Chakraborty, ²Tashfique Alam*

¹National Institute of Traumatology & Orthopaedic Rehabilitation (NITOR),
Sher-E-Bangla Nagar, Dhaka, Bangladesh

²Bangladesh Medical College Hospital, Dhaka, Bangladesh

INTRODUCTION

ACDF is a surgical mean for managing degenerative cervical disc disease and/or stenosis, acute cervical disc herniation and single level fracture-dislocation of cervical spine. Surgical intervention is indicated for decompression of the spinal cord and root in addition to realignment and stabilization of the spine. Several studies suggest that early surgical decompression leads to better neurological outcomes by preventing deleterious secondary effects of the initial spinal cord injury.

MATERIALS AND METHODS

A total of 356 patients (M-284, F-72) who underwent ACDF were studied from July, 2009 to March, 2017. Among them, 258 patients had cervical fracture-dislocation, 88 had degenerative disc disease and 10 had acute cervical disc herniation with myelopathic change. Steps included identification of the affected vertebra, discectomy and denudation of the articular cartilage of the superior and inferior vertebrae followed by insertion of autogenous iliac crest bone graft into the respective disc space and stabilization by plate and screws. Follow up period was 6 months to 8 years. Pre and post-operative assessment were done clinically, assessing radiology, comparing ASIA impairment scale and pain assessment through VAS and ODI scoring.

RESULTS

All patients survived surgery. No improvement in ASIA grading was observed in those having pre-operative ASIA impairment scale of A (46 patients). Other 310 patients (about 87%) had significant improvement in ASIA grading with a conversion into ASIA-E and ASIA-D. Post-operative complications included superficial wound infection and dysphagia in a few patients (2.1%) which were resolved conservatively. No patient needed revision surgery.

CONCLUSION

ACDF was satisfactory in treating patients with degenerative cervical disc disease, acute disc prolapse and single level cervical fracture-dislocation with varying degree of spinal cord compression. Adequate instrumentation and fusion prevented the patients from further deterioration and provided with long term satisfactory outcome.



SURGICAL MANAGEMENT OF O-C1-C2 INJURIES

Mehmet Aydogan

Bosphorus Spine Center, Turkey

Upper cervical injuries (UCI) consist of a diverse group of injuries that affect the skull base, the atlas, and the axis and are generally associated with high-energy trauma. These lesions are often serious but neurologic complications are rare in emergency; this is due to the fact that C1-C2 medullary injuries are fatal. In survivors, those lesions may cause chronic instability with pseudarthrosis or delayed neurologic complications. The overall prevalence of CSI in all trauma patients was 3.7%. And 20% of all cervical injuries are upper cervical.

Upper cervical injuries listed as; occipital condyle fractures, craniocervical dissociation, atlas fracture, atlantoaxial dislocation, dens fracture, and traumatic spondylolisthesis.

Surgical treatment of Upper spinal injuries should have three main goals: prevent further neurological injury, reduce and stabilize the injured segment, and provide long-term stability and/or prevent deformity.

The surgical management of upper cervical injuries contains, occiputocervical (O-C2) instrumentation, posterior C1-C2 instrumentation, anterior C2-C3 instrumentation.

In these lecture we aimed to give information about surgical treatment of upper cervical spine injuries, instrumentation, and techniques.

TLIF WITH CORTICAL PEDICULAR SCREW FIXATION

Dato' K S Sivananthan

Orthopaedics & Traumatology Department, Hospital Fatimah, Ipoh, Perak, Malaysia

RATIONALE

To compare the outcome of a minimally invasive technique using cortical pedicular screws for disectomy and fusion with those that used the traditional pedicular screw.

METHOD

Retrospective analysis of 36 patients using cortical pedicular screws for disectomy and fusion (TLIF) was compared with 36 cases using traditional pedicular screws. The length of stay in the hospital, post-operative pain medication and post-operative outcome were compared in this 2 series.

RESULTS

The length of stay in the hospital was shorter using the new technique. Post-operative pain medication was also less in the new technique and the length of the incision was also smaller. However at 6 months, there was no difference in outcome in the 2 series as regards fusion rate and complications.

CONCLUSION

Lumbar fusion using cortical pedicular screws is able to achieve the same results as the traditional open technique. However, the new technique used a smaller midline incision and there is less muscle disruption, the patient is able to go home early and use less post-operative medication.



MINI-ALIF WITH TRANSVERSE PARA-RECTAL INCISION

Jaeyoon Chung

Chonnam University Medical School, Gwangju Hyundae Hospital, Korea

Conventionally, anterior approach of lumbar spine for the interbody fusion needs long skin incision and wide dissection of abdominal muscles, consequently unacceptable long scar on the trunk. To minimize the muscular damage and long unsightly scar following wide exposure, the author has adopted a minimally invasive approach.

Patient was placed supine on the table with elevation of left side shoulder and pelvis about 10-30 degree. 4-8 cm long transverse skin incision is carried centered over left side lateral margin of Rectus abdominis muscle at the appropriate lumbar disc level, confirmed by X-ray. Anterior rectal sheath is transversely cut, and retracted toward right side. External, internal and transverse abdominis are separated along their fiber. Then, Transverse ligament behind Rectus muscle and deep to the transversalis muscle, conjoined tendon, is cut, and peritoneum is dissected bluntly from the lateral abdominal wall, down to the spine. Segmental vessels or ascending lumbar vein are tied and divided. Then spine is exposed by retracting aorta to right and psoas muscle to left. Two sets of Cloward retractors with extra-long blades were applied in cross angle direction.

During 1 year and 10 months period, 38 cases were performed in the various etiologic conditions including infection, fractures and pseudoarthrosis, etc. Skin incision was 4-8cm (Av. 5.3cm).

Incision was extended to 10cm, in two cases of L1-2 lumbar level, because of limitation in exposure, and in one L4-5 level spondylitis, due to the rupture of ascending lumbar vein.

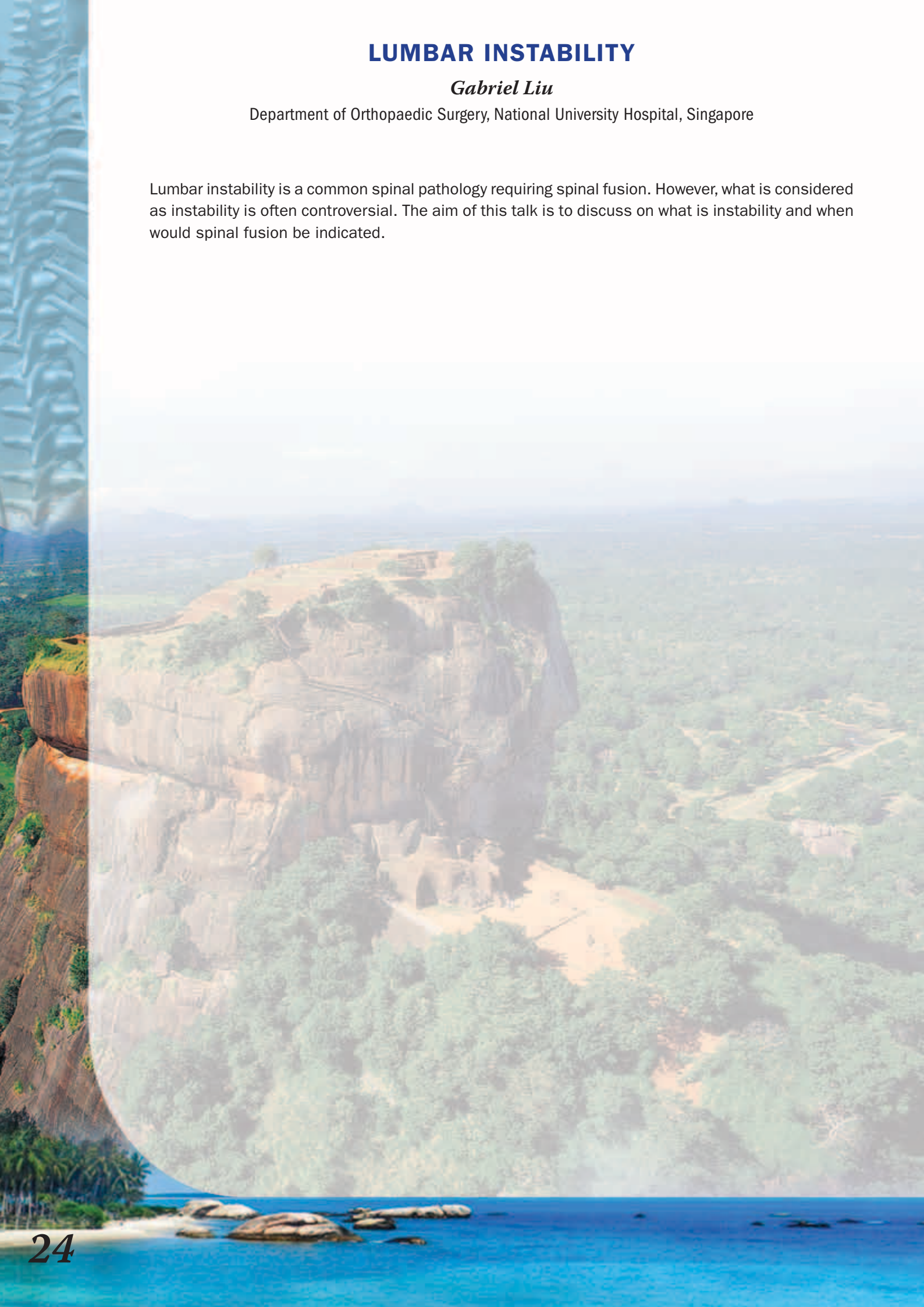
In conclusion, in most of one or two lumbar disc level fusion, this technique could be used with conventional surgical instruments.

LUMBAR INSTABILITY

Gabriel Liu

Department of Orthopaedic Surgery, National University Hospital, Singapore

Lumbar instability is a common spinal pathology requiring spinal fusion. However, what is considered as instability is often controversial. The aim of this talk is to discuss on what is instability and when would spinal fusion be indicated.





SELECTION OF FUSION LEVELS IN CORRECTIVE SURGERY FOR ADOLESCENT IDIOPATHIC SCOLIOSIS

Shu-Hua Yang

Section of Spinal Surgery, Department of Orthopedics, National Taiwan University Hospital, Taipei, Taiwan

The goals of corrective surgery for adolescent idiopathic scoliosis (AIS) include maintaining coronal and sagittal alignment, producing level shoulders, correcting deformity, and preserving motion segments especially in the lumbar spine. Several classification systems for AIS have been developed for surgical planning and for comparison of postoperative results. Even so, choosing the most appropriate levels in spinal fusion for AIS is still challenging.

As a general rule, structural curves are usually included in the spinal fusion for AIS. As stated in the Lenke classification, structural curves were defined as those that fail to correct to $< 25^\circ$ as measured on side bending radiographs and/or that have a segmental kyphosis of $> 20^\circ$ at PT (T2-5) or TL (T10-L2) curve. Some surgeons recommend spinal fusion should also include lumbar non-structural curve that are $> 45^\circ$ on standing PA radiographs or that are associated with clinically significant rotational prominences, or in the presence of wedging of apical vertebrae along with significant apical vertebral translation and rotation.

Criteria for selection of upper instrumented vertebra (UIV) include curve type, pre-surgical shoulder balance, magnitude and rigidity of proximal thoracic (PT) curve, PT kyphosis, vertebral rotation and apical translation of PT curve, direction of T1 tilt, and location of PT/MT transitional vertebra. Although the selection of UIV is considered as one of main factors of post-surgical shoulder balance, it seems not to be an independent predictor of shoulder balance.

Factors used in selection of lower instrumented vertebra (LIV) include curve rigidity, lumbar modifier, and characteristics of caudal lumbar vertebra. If only thoracic curves are to be fused, such as Lenke type 1A or 2A curves, the most cephalad vertebra that is merely touched by the central sacral vertical line (CSVL) is usually selected as the LIV. If lumbar curve should be included in the spinal fusion, selection of LIV is influenced by its relationship to the CSVL, the flexibility of the disc caudal to the proposed LIV, and axial plane rotation and flexibility. Long-term outcome is improved if at least three distal discs could be saved.

Concept of selective thoracic fusion (STF) was introduced for preserving lumbar mobile segments by fusing only the major thoracic curve and leaving minor lumbar curve unfused. However, the risk of decompensation should be carefully considered. Two most possible causes of decompensation after STF are overcorrection of the thoracic curve and incorrect identification of the lumbar curve. Selective thoracolumbar or lumbar fusion for Lenke type 5C or 6C curves should be reserved only when the thoracic curve is flexible and the patient is reaching the end of skeletal maturity

Although several algorithms have been proposed to determine fusion levels for AIS surgery, definite guideline for selection of fusion levels have still not been established yet. Numerous characteristics of AIS have to be taken into consideration while choosing fusion levels. Treatment needs to be individualized to each patient. While trying to reduce the number of fusion segments, careful selection of patients and fusion levels is crucial to avoid complications. Comprehensive validation studies about debated issues are still warranted to answer unsettled questions on selection of fusion levels in corrective surgery for AIS.

NON-FUSION GROWTH MODULATION FOR THE TREATMENT OF JUVENILE IDIOPATHIC SCOLIOSIS

*Pankaj Kandwal **, *Arvind Jayaswal***

*Additional Professor Department of Orthopaedics, All India Institute of Medical Sciences, Rishikesh, India

**Head of the Department of Spine Surgery, Primus Super Speciality Hospital, New Delhi, India

Early Onset Scoliosis (EOS) is the term applied for Scoliosis presenting before the age of 10 years or less. Infantile & Juvenile Idiopathic Scoliosis are the common types of EOS, besides congenital, neuromuscular & syndromic types.

These deformities pose a major challenge to the treating surgeon because of the rapid progression of the deformity due to spinal growth and also the subsequent effect on thoracic & lung growth (RM Campbell 2003). Non fusion growth sparing procedures have evolved to allow for the spinal & thoracic growth in the treatment of these immature spines till or just before the skeletal maturation.

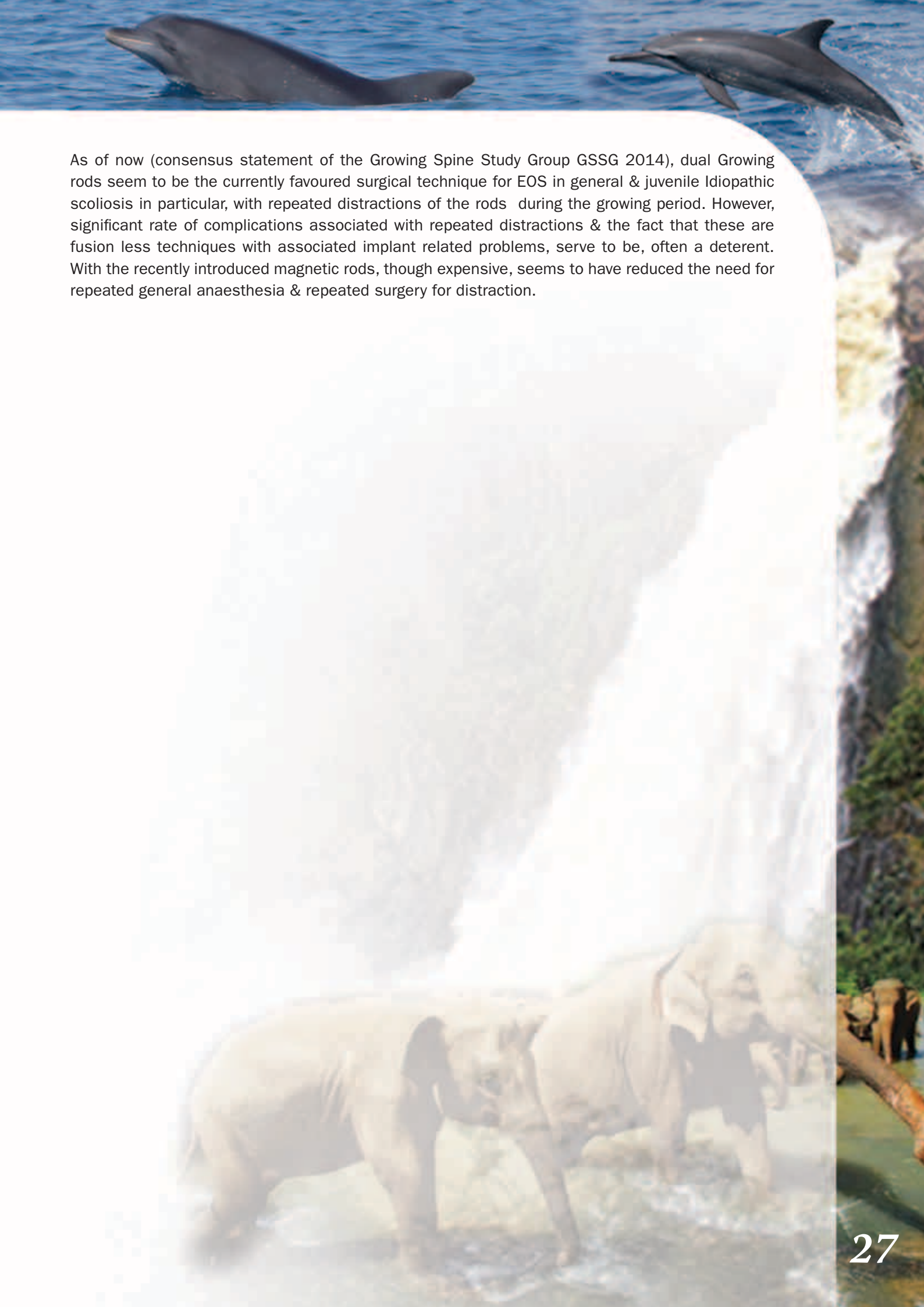
These growth-friendly surgical techniques can follow a distraction-based (Growing Rods [GR], Vertical Expandable Prosthetic Titanium Rib [VEPTR]), guided-growth (Luque Trolley technique, Shilla technique), or compression-based (Tethers, Staples) strategy. The goal of these surgeries is to halt progression of the curve and correct the deformity in the coronal and sagittal planes, keeping in mind the mobility of spine, growth of the spinal column and the thorax (pulmonary function).

Originally described by Harrington and modified by Moe, the distraction-based technique has undergone several modifications that allow for control of the deformity while minimizing complications. These distraction-based implants can be attached to the spine (**Growing Rods**), ribs (**VEPTR**), or pelvis depending on patient age, characteristics of the curve, and available bone stock. Frequent lengthenings not only improve curve correction but also T1-S1 length. Magnetic Growing Rods (MCGR) were introduced to circumvent complications related to repeated surgeries. The MCGR system comprises a magnetically distractible spinal rod implant and an external remote controller, which lengthens the rod.

The Guided growth technique was introduced by Luque and modified by Ouellet. The concept was later extrapolated in **Shilla** technique where the apex is fused and the gliding anchors at the ends allow the spine to grow. The radiologic outcome and complication are comparable between Shilla technique with GR technique, however number of procedures/surgeries is significantly lower in Shilla technique.

Compression based technique is based on Hueter-Volkman principle, i.e increased pressure across a growth plate in the vertebral body slows growth. **Vertebral body stapling** and flexible **tethers** is compression based technique used for juvenile idiopathic scoliosis.

These devices act as internal splint/brace till the patient attains skeletal maturity when the definitive fusion procedures can be embarked upon.



As of now (consensus statement of the Growing Spine Study Group GSSG 2014), dual Growing rods seem to be the currently favoured surgical technique for EOS in general & juvenile Idiopathic scoliosis in particular, with repeated distractions of the rods during the growing period. However, significant rate of complications associated with repeated distractions & the fact that these are fusion less techniques with associated implant related problems, serve to be, often a deterrent. With the recently introduced magnetic rods, though expensive, seems to have reduced the need for repeated general anaesthesia & repeated surgery for distraction.

ADOLESCENT IDIOPATHIC SCOLIOSIS – EVALUATION AND SURGICAL STRATEGIES

Udai De Silva

Department of Orthopaedics, Provincial General Hospital, Badulla, Sri Lanka

Scoliosis is a complex, three-dimensional deformity of the spine that comprises a lateral curvature, thoracic lordosis and a posterior rib hump. If left untreated, the condition results in altered spinal mechanics and degenerative changes which lead to pain and loss of spinal mobility. Adolescent idiopathic scoliosis (AIS) is the commonest type of scoliosis in children between 10 and 18 years and affects 1 in 250 adolescents. AIS curves progress during the rapid growth period and slow their progression afterwards. The surgical treatment is often indicated in adolescents whose curves are greater than 45° while still growing as these curves tend to progress even after skeletal maturity.

AIS is evaluated by observing the adolescent's posture in a 360° fashion. The head, neck and pelvis should normally be in the midline and the body asymmetry is checked while considering abnormalities in shoulders, scapulae, arms, hips and legs. Adam's forward bending test with an inclinometer which helps to better understand the amount of torso asymmetry, assessment for ligament laxity for connective tissue disorders and thorough neurologic examination including abdominal reflexes completes the clinical evaluation. The radiological evaluation includes standing anteroposterior and lateral views of full spine from S1 upwards, supine side bending anteroposterior views and a supine anteroposterior view under traction. Lenke Classification system is of utmost importance in evaluation in order to decide the further management and it is entirely based on the radiological evaluation of proximal thoracic curve, main thoracic curve, thoracolumbar curve and lumbar curve, Centre Sacral Vertical Line and thoracic kyphosis using the Cobb's method. Lenke Classification categorizes the AIS patient into one of 6 Types. CT and MRI are useful adjuncts in the assessment.

The goal of surgery is to prevent curve progression by fusion with bone grafts supported by instrumentation and to achieve some curve correction. The surgical strategy is either posterior approach or anterior approach and in very stiff, high magnitude curves there is a place for combined anterior and posterior surgery as a single or two stage procedure. The surgical strategy is usually based on the classification of AIS (Lenke), skeletal maturity and the remaining growth, curve magnitude and stiffness of the curves.

Posterior fusion with instrumentation has long been the standard for the surgical treatment of AIS. The last two decades saw a gradual shift of usage of all-pedicle screw systems with more anchors to the spine which has enabled greater anchorage and correction manoeuvres and reduced the implant failure rate and increased fusion rates. In high magnitude, stiffer curves posterior osteotomies in the form of Ponte osteotomies are employed and although they cause added morbidity to the procedure they give the surgeon the freedom of achieving better curve correction. Anterior surgery was previously favoured for thoracic and lumbar scoliosis and enables shorter fusion levels with multilevel discectomies and convex epiphysiodesis with bone grafting with or without instrumentation. Modern techniques with segmental spinal posterior instrumentation reliably provide a better arrest of curve progression and achieve greater correction of the curves in the coronal plane (30% to 90%) with minimal loss at follow-up and also achieve a spontaneous partial correction of the compensatory curves and improve appearance.



CONGENITAL SCOLIOSIS – MANAGEMENT PRINCIPLES

Yat Wa Wong

Department of Orthopaedics and Traumatology, The University of Hong Kong,
Queen Mary Hospital, Hong Kong

Congenital scoliosis is due to anomaly of vertebrae that develops during in utero period. The exact cause is not known and it is associated with congenital problems of neural axis, cardiovascular system, genitourinary tract and musculoskeletal anomalies. Clinicians should investigate the corresponding organ systems especially for patients who may need surgical intervention to their spine. The pathogenesis of congenital scoliosis can be attributed to failure of formation, failure of segmentation, hemimetameric shift, failure of midline fusion, mixed type and complex malformation. We may predict the prognosis for deformity progression by analysing the exact vertebral anomaly, location of the bony defect, age and the presence of associated rib fusion. Most patients are asymptomatic. The spinal deformity may not be apparent at birth but gradually develops after skeletal growth. Mild deformity or low risk patients can be observed. Brace treatment in general is not effective but sometimes can be used control the compensatory curves. If the deformity is significant and likely to progress, surgical intervention is indicated. The surgical options include halo traction, in situ fusion, convex hemiepiphysiodesis, hemivertebra excision, growing rods, osteotomy and vertebral column resection. The choice of surgery depends on the severity of the deformity, pathoanatomy, age and the expertise of the surgeons.

MANAGEMENT OF POST-TB KYPHOSIS

Muhammad Tariq Sohail

Doctors Hospital and Medical Center, Lahore, Punjab, Pakistan

Classic Spinal Tuberculosis is kyphogenic, producing various degree of kyphosis or kyphotic deformity. Patients either presents with kyphotic deformity or with neurological symptoms.

Degree of deformity depends on various factors like single motion segment or multilevel involvement, location of the disease and extent of the activity / number of vertebrae involved.

The importance of spinal deformity is multifold, not only producing a sagittal imbalance but also puts neurological structures at risk. The type of deformity and extent of deformity is different from adult to child and in both age groups presents their own challenges more so in pediatrics group. Principles of deformity correction of Post- tuberculosis kyphosis are presented.



MANAGEMENT OF SPINAL METASTASIS

Chris Yin Wei Chan

Spine Unit, University of Malaya, Kuala Lumpur, Malaysia
University Malaya Medical Centre, Kuala Lumpur, Malaysia

Early detection with advanced diagnostic tools combined with prolonged survival for patients with malignancies have led to an increase in incidence of spinal metastasis. In such patients, the surgical decision is controversial due to high risk of surgical complications and guarded prognosis in terms of long term survival. However, Patchell's landmark publication on direct decompressive surgery combined with radiotherapy compared with radiotherapy alone in maintaining neurological function and prolonging survival have proven the efficacy and superiority of surgery in patients with Metastatic Epidural Spinal Cord Compression (MESCC). The Mayo algorithm published by Walker et.al. emphasised on the clinical indications for surgery in patient with spinal metastasis and the increased availability of stereotactic radiosurgery could lead to a shift in treatment approach with the use of the NOMS framework. This presentation will mainly focus on these treatment algorithms and its application in clinical practice and we will also share our experience on management spinal metastasis using long construct minimally stabilisation using percutaneous pedicle screw.

