



Asia Pacific Spine Society (APSS)

(Spine Section of APOA)

APSS DEPUY SYNTHES SPINE TRAVELLING FELLOWSHIP REPORT

03 Dec 2021 to 24 Dec 2021

Fellow: Dr Naveen Agarwal

MBBS, MS (Orthopaedics), FASSI (Spine Surgery).

Assistant Professor, Department of Orthopedic Surgery

Govt. Medical College, Haldwani,

Uttarakhand, India.

Host: Professor S. Rajasekaran.

M.S., DNB, F.R.C.S.[Ed], M.Ch[Liv.] , F.R.C.S. [Eng], PhD

Chairman, Department of Orthopaedics and Spine Surgery

Ganga Hospital, Coimbatore, India





Asia Pacific Spine Society (APSS)

(Spine Section of APOA)

Introduction

The Asia Pacific Orthopedic Association (APOA)/Asia Pacific Spine Society (APSS) – Depuy Synthes Spine Travelling Fellowship 2020, I had been selected for was scheduled from 17 September 2020 to 7 October 2020. But due to COVID-19 it was postponed to May 2021 to June 2021. Again it was postponed due to second wave of COVID-19. During this time APSS secretariat was continuously in touch with me and looking for options for getting my fellowship done. Then in November 2021 I was given three options to choose from for my fellowship. Options were: 1. Local Fellowship, 2. Virtual Fellowship and 3. Withdraw. I took my time and decided to go for Local fellowship at Ganga Hospital Coimbatore for 3 weeks from 3rd December 2021 to 24th December 2021, as I had been waiting for this fellowship for more than a year.

Firstly, I would like to thank the APSS for giving me this opportunity and Prof. Dr S Rajasekaran Sir for making my fellowship a rich and valuable experience.

Before my arrival at Ganga Hospital, Coimbatore, I was in continuous touch with Jennifer APSS and Mr. Mohan Secretary to Prof. Dr S Rajasekaran Sir regarding my logistics. My Airport transfers and accommodation was well arranged.

My Fellowship schedule started with orientation day on 3rd December 2021 when department staff/ coordinator nurse briefed me on the infrastructure and the hospital. The details of the weekly schedule were told to me and the secretary of division helped me and regularly gave necessary information and updates. I was accompanied by two other travelling fellows: Dr Asraf ul Matin (AO spine fellow) and Dr Sarwar Jahan (APSS Ganga Fellow), they both were from Bangladesh.

Accommodation provided to me was pleasant, spacious, conveniently located and within short distance from all efficient public transport system of Coimbatore. It was also very near to restaurants and stores.






Asia Pacific Spine Society (APSS)

(Spine Section of APOA)

Clinical Meetings

The department had system of Clinical case presentations, Journal club, bi weekly audit of cases and seminars on Tuesday and Thursday with all faculties, residents, and fellows. Each patient's clinical details, radiology, pre-op plans, post-op management (both medical and rehab part) was discussed in detail. Every one of us was actively involved in discussions for patient management. All faculties encouraged me to put my views and opinions for patient care. They always appreciated me for all important points added and also corrected me when I was wrong. They cleared all my doubts whenever raised and made my learning more comprehensive.



Ganga Hospital had great number and variety of patients in wards including deformity, degenerative, trauma, syndromic affections, infections, spinal metastasis. I had great opportunity to enhance my understanding of management principles and options for this variety of cases from paediatric to geriatric patients. Easy availability of patient details, investigations and radiology on Electric Medical record system was a great help combined with the helping nature of fellows.



Asia Pacific Spine Society (APSS)

(Spine Section of APOA)

Operative Exposure

I was privileged to see a good number of deformity cases which was the main charm including complex neuromuscular, syndromic (NF, Marfan), congenital and idiopathic scoliosis apart from many degenerative, trauma and TB spine cases.

They use intra-operative Neuro-monitoring, operating microscope, burr and ultrasonic bone-scalpel routinely. It was good to learn tips and tricks from experts. Use of fulcrum bending views for pre-op planning and correlation with intra-op correction achieved was new method to learn for me. Cervical laminectomy with cervical pedicle screw fixation was a routine procedure for Cervical Myelopathy cases and I learnt better technique to put in cervical pedicle screw. Watching SR sir (Prof. S Rajasekaran is known by this name in hospital) perform cervical pedicle screw fixation made it look very easy.

All faculties Dr Ajoy Prasad Shetty, Dr Rishi Kanna, Dr Vijay Anand and Dr Vibhu sir allowed me to be actively involved in operative procedures and also encouraged me to point out the differences I noticed and discuss them. This opened horizons of my thinking over many aspects of surgical care and practices. One thing I found very interesting was that 90% of lumbar canal stenosis were not subjected to lumbar fusion surgery and were managed with micro decompression alone. This is something which I am going to change in my practice and protocol for management of lumbar canal stenosis patients.

I also learnt technique of endoscopic spine surgery, this was the first time I was exposed to endoscopic lumbar discectomy. After understanding the basics of endoscopic procedures, I am planning for attending the course targeting only endoscopic spine surgery and start performing endoscopic procedures at my centre as well.

SR sir and all other faculty members were very enthusiastic discussing tips and tricks of spine surgery and how to bring changes in our practice as well. All were very prompt in clearing our doubts.





Asia Pacific Spine Society (APSS)

(Spine Section of APOA)

MIDAS REX HANDS ON WORKSHOP

We got the opportunity to be part of Hands on workshop (04.12.2021) on electrical burr (Midas Rex) under the supervision of Prof. Dr S Rajasekaran Sir, Dr A P Shetty sir and Dr Rishi Kanna Sir. It was very good learning experience, as we got to understand about different types of burr tips and technique of using the burrs.



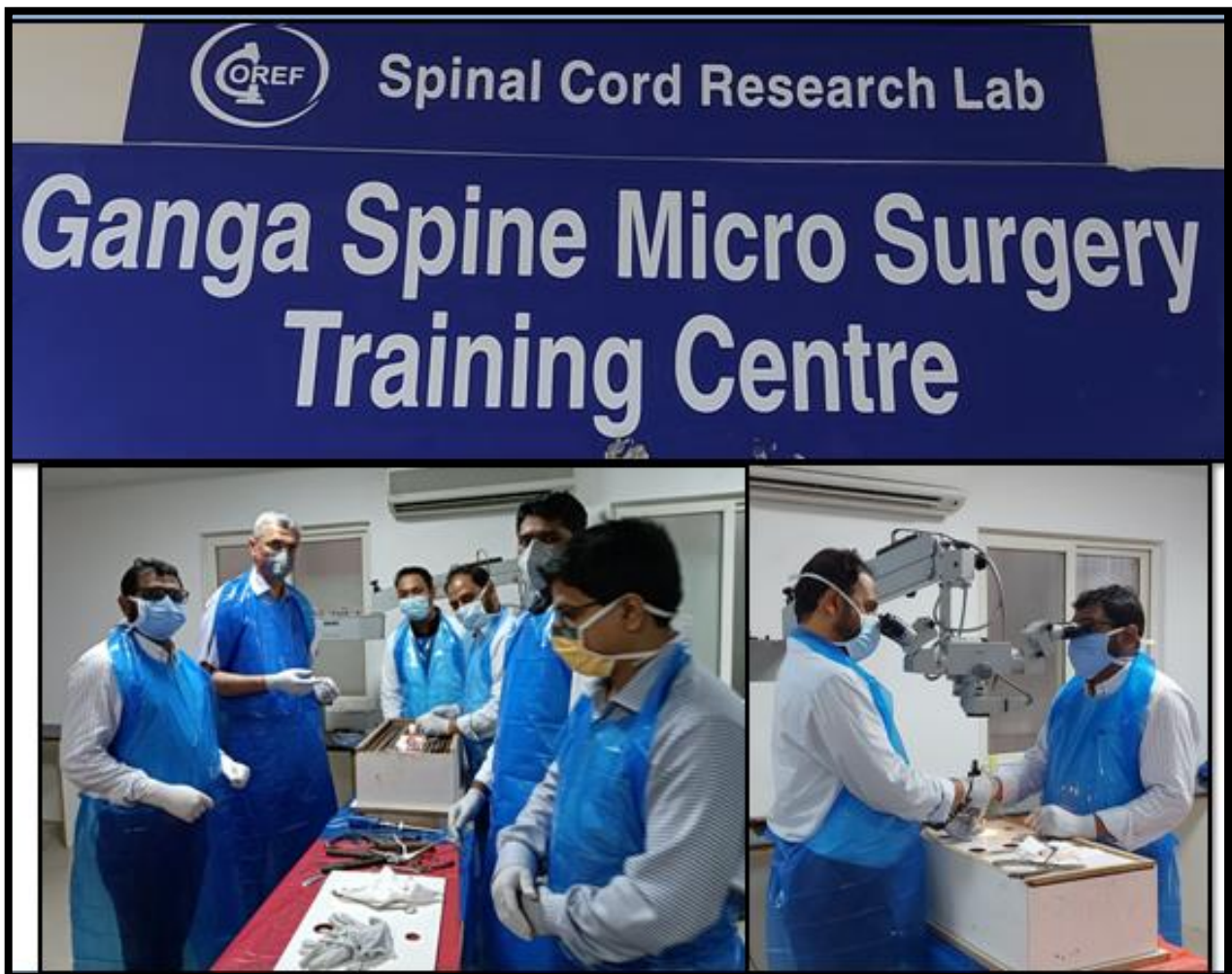

Asia Pacific Spine Society (APSS)

(Spine Section of APOA)

HANDS ON WORKSHOP ON MICROSCOPE

A hands on workshop on Microscope was organized especially for us (Travelling fellows) on 10.12.2021, although the microsurgery lab was closed for about one and half year due to COVID We got the opportunity to work with microscope on animal cadaveric spine. Did Dural tear repair, lumbar micro decompression and anterior cervical corpectomy under Microscope. I am very thankful to Prof. Dr S Rajasekaran sir and Dr Ajoy shetty Sir for organizing the workshop.



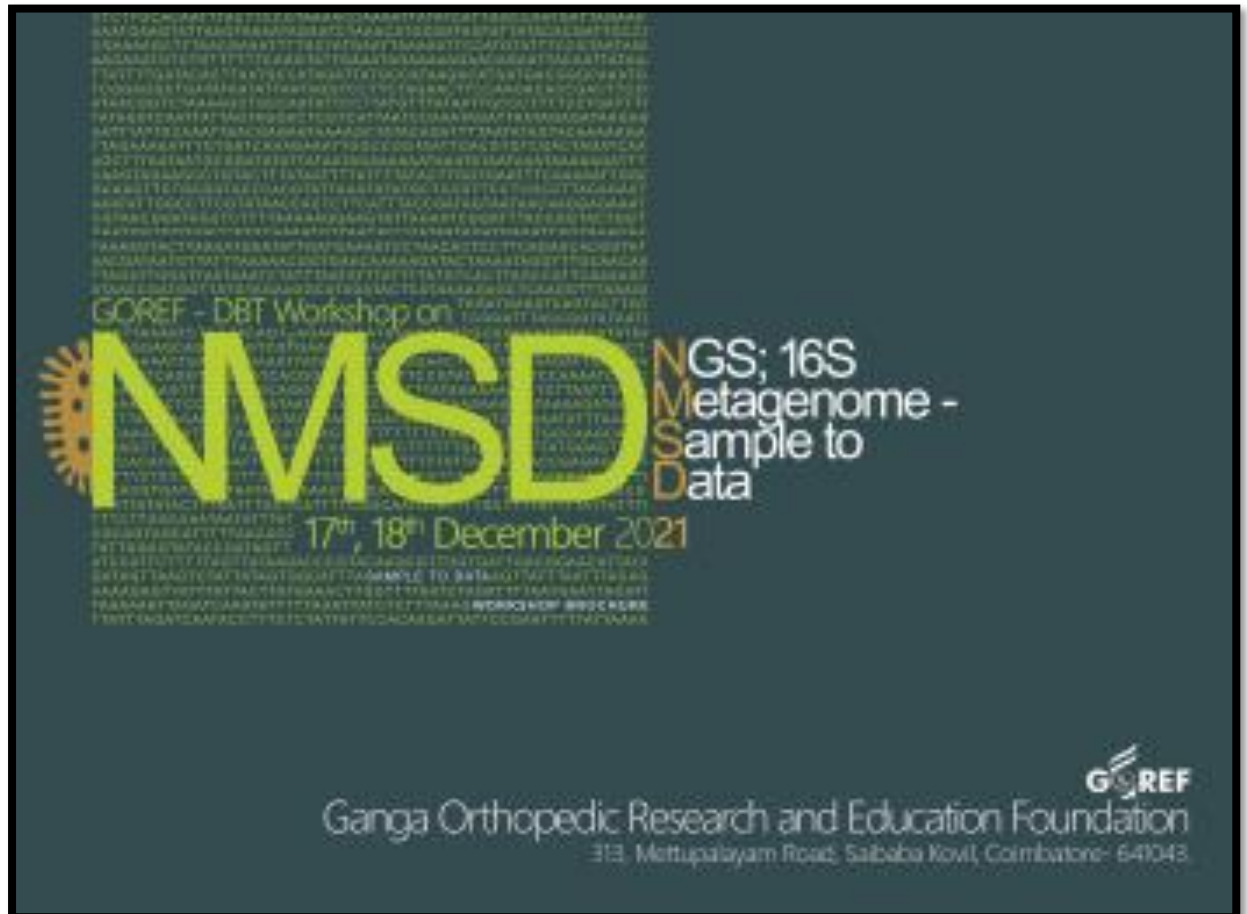


Asia Pacific Spine Society (APSS)

(Spine Section of APOA)

NMSD (Workshop on Next Gen Bacterial genome sequencing)

On 17th and 18th December a workshop on Next Gen Genome sequencing was organized and this workshop gave us the insight of how important bacterial microbiota is for us. Got the opportunity to know the level of research work being carried out by Ganga Hospital under the guidance of SR sir.

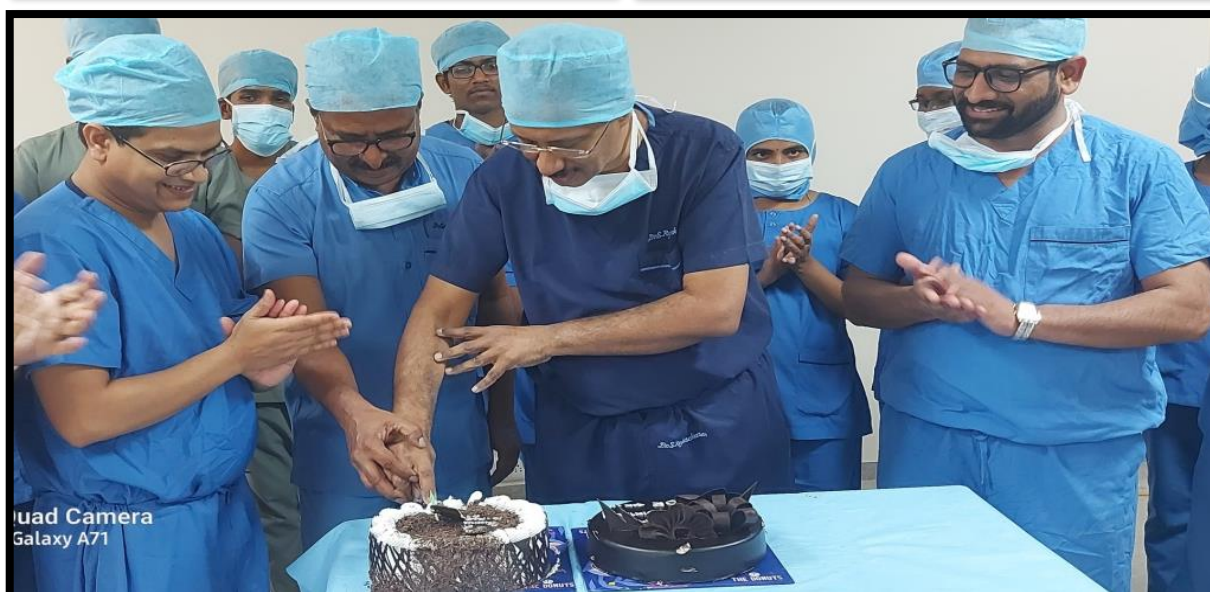



Asia Pacific Spine Society (APSS)

(Spine Section of APOA)

Memorable Moments of OT and OPD



Birthday Celebration of SR sir on 17.12.21



Asia Pacific Spine Society (APSS)

(Spine Section of APOA)

Leisure times. Food and sight-seeing



Dinner hosted by Prof. S Rajasekaran Sir for me and my colleagues from Bangladesh at “**Hash Six**”.



Vegetarian food at “**Aboorva’s restaurant**” - Famous in Coimbatore



Asia Pacific Spine Society (APSS)

(Spine Section of APOA)



Lunch by Dr Ajoy Sir at “**Chettinad Canteen**”—a delicious South Indian food experience.





Asia Pacific Spine Society (APSS)

(Spine Section of APOA)

Glimpse of South Indian food- Served on “Banana leaf”





Asia Pacific Spine Society (APSS)

(Spine Section of APOA)

Trip to Yercard, Coonor, Ooty and Isha Foundation





Asia Pacific Spine Society (APSS)

(Spine Section of APOA)





Asia Pacific Spine Society (APSS)

(Spine Section of APOA)

Log Book

S.No	Date	Age	Gender	Diagnosis	Procedure	Surgeon	Role
1	03.12.21	54	Male	T6-7 extradural Nerve sheath Tumour ?Schwannoma	Tumour excision and biopsy with Pedicle screw fixation	Prof. S Rajasekaran	Observer
2	03.12.21	70	Male	L4/5 Stenosis with right radiculopathy	L4/5 MLD	Dr A P Shetty	Observer
3	03.12.21	61	Male	L3/4 and L4/5 Degen Listhesis with stenosis	L3/4 and L4/5 TLIF	Dr A P Shetty	Observer
4	03.12.21	40	Female	Odontoid Fracture with Stable Hangman Fracture	Odontoid screw fixation	Prof. S Rajasekaran	Observer
5	03.12.21	81	Male	C7/T1 Fracture In AS	ACDF C6/7	Dr A P Shetty	Observer
6	03.12.21	50	Male	L4/5 Disc prolapse with bilateral radiculopathy	L4/5 MLD	Dr A P Shetty	Observer
7	03.12.21	21	Male	L3/4 and L4/5 Right sided PID	L3/4 and L4/5 MLD	Dr A P Shetty	Observer
8	03.12.21	29	Male	L4/5 Stenosis with right radiculopathy	L4/5 Microdecompression	Dr A P Shetty	Observer
9	03.12.21	55	Female	L4/5 Spondylolisthesis	L4/5 TLIF	Dr Rajasekaran	Observer
10	03.12.21	64	Male	C5/6 DOC	C5/6 ACDF	Dr A P Shetty	Observer
11	04.12.21	14	Female	Thoracolumbar Kyphosis T12 hemi	PI fixation from T9-L2	Dr A P Shetty	Observer
12	04.12.21	64	Male	C5-C6 PID with Cord myelopathy	ACDF C5/6`	Dr A P Shetty	Observer
13	04.12.21	47	Male	L3/4 and L4/5 PID with nerval compression	L3/4 and L4/5 Decompression	Dr A P Shetty	Observer
14	04.12.21	86	Male	C4/5 Injury B3	C3-C6 Anterior plating with C4/5 Cage	Dr Rishi Kanna	Observer
15	04.12.21	70	Female	L1/2 Spondylodiscitis	Lumbar foxation and decompression	Dr Rishi Kanna	Observer



Asia Pacific Spine Society (APSS)

(Spine Section of APOA)

16	06.12.21	65	Male	Ankylosing spondylitis with thoracolumbar kyphosis and chest on knee deformity	L3 PSO with deformity correction	Prof. S Rajasekaran	Observer
17	06.12.21	56	Male	Atlanto occipital Assimilation and basal invagination with Nurisk grade 4 myelopathy	Occipito cervical fixation with pedicle screw and foraman magnum decompresison	Prof. S Rajasekaran	Assisted
18	06.12.21	55	Male	C5-C7 segmental OPLL	C6 corpectomy	Dr Rishi Kanna	Observer
19	06.12.21	50	Male	C4/5 Disc Osteophyte complex (DOC)	C4/5 ACDF	Dr Rishi Kanna	Assisted
20	06.12.21	55	Female	T6 Pathological Collpase with prevertebral Abscess and mutlilevel spondylitis	PI fusion T3-T9 with interbody fusion	Dr Rishi Kanna	Observer
21	06.12.21	76	Male	L4/5 Spondylitis with bilateral neurodeficit	PI decompresison, debridement, biopsy and fusion with TLIF	Dr Rishi Kanna	Observer
22	07.12.21	23	Male	C3-4 and C5/6 DOC with myelopathy	C3-4 and C5-6 ACDF	Dr Rishi Kanna	Assisted
23	07.12.21	28	Male	L3/4 PID with stenosi	Microdecompression	Dr Rishi Kanna	Observer
24	07.12.21	40	Male	L3/4 Adjacent segemnt disease with implant failure at L4/5	Extension of fusion to L3/4 with implant revision at l4/5	Dr Rishi Kanna	Assisted
25	07.12.21	51	Male	L2 burst fracture	D12 to L3 fixation	Dr Rishi Kanna	Observer
26	08.12.21	9	Female	Congenital left thoracis scoliosis with Unsegmented bar	Deformity correction with Concave osteotomy and bar excision	Prof. S Rajasekaran	Observer
27	08.12.21	39	Male	L5/S1 PID with left sided radiculopathy	Endoscopic L5/S1 discectomy	Dr A P Shetty	Observer



Asia Pacific Spine Society (APSS)

(Spine Section of APOA)

28	08.12.21	71	Female	T12/L1 PID with right radiculopathy	T12 L1 decompression and discectomy with T11 to L1 fixation	Dr A P Shetty	Assisted
29	08.12.21	10	Male	Congenital Left TL scoliosis with Growth rod in situ	Growth rod distraction	Dr A P Shetty	Observer
30	08.12.21	40	Male	L5/S1 PID with left radiculopathy	Microscopic Discectomy	Prof. S Rajasekaran	Observer
31	08.12.21	58	Male	L4/5 PID with left radiculopathy	Tubular discectomy	Dr A P Shetty	Observer
32	08.12.21	30	Male	L4/5 Recurrent PID	Revision Microdiscectomy	Dr A P Shetty	Observer
33	08.12.21	69	Female	L4/5 Grade I Lytic spondylolisthesis	L4/5 decompression and fusion	Dr A P Shetty	Observer
34	08.12.21	50	Male	T10/11 B2 injury	MIS fixation T10 to T12	Dr A P Shetty	Assisted
35	08.12.21	67	Female	C6/7 retrolisthesis with myelopathy with L1 osteoporotic fracture	C6 corpectomy and L1 VTP	Dr A P Shetty	Observer
36	09.12.21	30	Male	C1 burst fracture with type II odontoid fracture	Occipito cervical fixation	Dr Rishi Kanna	Assisted
37	09.12.21	70	Female	L1/2 Spondylodiscitis	Posterior instrumented fusion and biopsy	Dr Rishi Kanna	Observer
38	09.12.21	50	Male	C5/6 DOC with myelopathy Nurick Grade I	C5/6 ACDF	Dr Rishi Kanna	Assisted
39	09.12.21	20	Male	L5/S1 PID	L5/S1 endoscopic discectomy	Dr Rishi Kanna	Observer
40	10.12.21	54	Male	L5 IDEM	Tumour excision and biopsy	Dr Rajasekaran	Observer
41	10.12.21	58	Female	L4/5 listhesis	L4/5 TLIF	Dr Ajoy	Observer
42	10.12.21	70	Male	L4/5 and L5/S1 Stenosis	L4/5 and L5/S1 Microdecompression	Prof. S Rajasekaran	Observer



Asia Pacific Spine Society (APSS)

(Spine Section of APOA)

43	10.12.21	48	Male	L3/4 and L4/5 Stenosis	L3/4 and L4/5 Microdecompression	Dr A P Shetty	Assisted
44	10.12.21	42	Female	L4/5 degen listhesis with L5/S1 lytic listhesis	L4-S1 TLIF	Dr A P Shetty	Observer
45	10.12.21	61	Female	T2 extradural and paraspinal schwanoma	Tumour Excision and Biopsy	Dr A P Shetty	Assisted
46	10.12.21	60	Male	L4/5 left sided PID	L4/5 Microdiscectomy	Dr A P Shetty	Observer
47	11.12.21	37	Male	C4/5 PID with right sided radiculopathy	C4/5 ACDF	Dr A P Shetty	Observer
48	11.12.21	54	Male	C4/5 PID with Myelopathy	C3/4 ACDF	Dr A P Shetty	Assisted
49	13.12.21	11	Female	AIS lenke 3C	T4-L3 PI fusion and deformity correction	Prof. S Rajasekaran	Observer
50	13.12.21	52	Male	L4/5 PID	L4/5 decompression and fusion	Prof. S Rajasekaran	Observer
51	13.12.21	60	Female	Odontoid non union with high cervical myelopathy	C1-C3 fixation and Fusion with Harms Cage insertion	Prof. S Rajasekaran	Assisted
52	13.12.21	45	Male	L3/4 and L4/5 Stenosis	L3/4 and L4/5 Microdecompression	Prof. S Rajasekaran	Observer
53	13.12.21	39	Male	C6/7 PID with radiculopathy	C6/7 ACDF	Prof. S Rajasekaran	Assisted
54	13.12.21	72	Male	C3-C7 DOC with myelopathy	C3-C7 PI with C3-C6 laminectomy	Dr Rishi Kanna	Observer
55	13.12.21	61	Female	L4/5 PID with left radiculopathy	L4/5 Microdiscectomy	Dr Rishi Kanna	Observer
56	13.12.21	65	Male	L4/5 recurrent PID	L4/5 decompression and fusion	Dr Rishi Kanna	Observer
57	13.12.21	50	Male	L2/3 PID	L2/3 TLIF	Dr Rishi Kanna	Assisted
58	13.12.21	42	Female	C3/4 and C4/5 DOC	C3/4 and C4/5 ACDF	Dr Rishi Kanna	Observer
59	13.12.21	55	Female	C5/6 DOC with myelopathy Nurick Grade I	C5/6 ACDF	Dr Rishi Kanna	Observer
60	14.12.21	31	Male	C5/6 and C6/7 DOC	C5/6 and C6/7 ACDF	Dr Rishi Kanna	Observer



Asia Pacific Spine Society (APSS)

(Spine Section of APOA)

61	14.12.21	35	Male	L4/5 PID	L4/5 Microdecompression	Dr Rishi Kanna	Assisted
62	14.12.21	13	Male	C5 pedicle osteoid osteoma	Tumour excision	Dr Rishi Kanna	Observer
63	14.12.21	53	Male	C6/7 DOC with Myelopathy	C6/7 ACDF	Dr Rishi Kanna	Assisted
64	15.12.21	59	Male	C2-7 OPLL with CSM	C2-C7 PIF and en bloc laminectomy C3-C6	Prof. S Rajasekaran	Observer
65	15.12.21	76	Male	C3-C6 OPLL with CSm	C3-7 enbloc laminectomy	Prof. S Rajasekaran	Observer
66	15.12.21	70	Male	C3-7 DOC with CSM	C3-C7 PI with C3-C6 laminectomy	Prof. S Rajasekaran	Assisted
67	15.12.21	40	Male	C3-C7 Segmental OPLL with CSm	C3-C7 PI with C3-C6 laminectomy	Prof. S Rajasekaran	Observer
68	15.12.21	76	Male	L3/4 and L4/5 Stenosis	L3-L5 Microdecompression	Dr A P Shetty	Observer
69	15.12.21	52	Female	L5/S1 PID	Endoscopic L5/S1 discectomy	Dr A P Shetty	Observer
70	15.12.21	72	Male	L3/4 and L4/5 Stenosis	L3-L5 Microdecompression	Dr A P Shetty	Assisted
71	15.12.21	42	Male	L4/5 PID	L4/5 Microdiscectomy	Dr A P Shetty	Observer
72	15.12.21	72	Female	L4/5 PID	L4/5 Microdiscectomy	Dr A P Shetty	Observer
73	15.12.21	11	Male	L4/5 inferior endplate avulsion	L4/5 decompression and discectomy	Dr A P Shetty	Assisted
74	15.12.21	72	Female	L2-L4 canal stenosis with L4/5 instabilitywith stenosi	L2-L4 decompression with L4/5 fusion	Dr A P Shetty	Observer
75	15.12.21	47	Male	L4/5 PID	L4/5 Microdiscectomy	Dr A P Shetty	Observer
76	15.12.21	50	Female	L4/5 PID	L4/5 Microdiscectomy	Dr A P Shetty	Assisted
77	15.12.21	38	Male	L4/5 PID	L4/5 Microdiscectomy	Dr A P Shetty	Observer



Asia Pacific Spine Society (APSS)

(Spine Section of APOA)

78	15.12.21	67	Male	L2-L4 canal stenosis with L4/5 instability with stenosis	L2-L5 decompression with L4/5 fusion	Dr A P Shetty	Observer
79	15.12.21	56	Male	L4/5 PID	L4/5 Microdiscectomy	Dr A P Shetty	Observer
80	15.12.21	56	Female	T12- L1 Spondylodiscitis	T9- L2 fusion , decompression and debridement	Dr A P Shetty	Assisted
81	15.12.21	58	Female	T2-T4 spondylodiscitis	PI fusion with debridement and biopsy	Dr A P Shetty	Observer
82	15.12.21	65	Female	Old T12 fracture with Neurodeficit	PI fusion and decompression	Dr A P Shetty	Observer
83	16.12.21	46	Male	L5/S1 PID with hypoplastic L5 Pars	L5/S1 TLIF	Dr Rishi Kanna	Observer
84	16.12.21	53	Male	L4/5 Grade I degenerative listhesis	L3-L5 decompression with fusion	Dr Rishi Kanna	Assisted
85	16.12.21	59	Male	T12-L1 AO B2 injury	PI fixation	Dr Rishi Kanna	Observer
86	16.12.21	26	Male	Operated case of L3/4 AO type C injury	L5 screw removal and rod exchange	Dr Rishi Kanna	Observer
87	16.12.21	68	Male	L4/5 degenerative listhesis with L5/S1 facet arthropathy	L4-S1 TLIF	Dr Rishi Kanna	Observer
88	17.12.21	57	Male	C4/5 DOC	C4/5 ACDF	Dr A P Shetty	Assisted
89	17.12.21	46	Female	T10-L2 OLF with L2/3 ASD	T9- Pelvic fusion and OLF excision	Dr A P Shetty	Observer
90	17.12.21	29	Male	T10-11 Recurrent left paraspinal tumour	Tumour excision and biopsy	Prof. S Rajasekaran	Observer
91	18.12.21	16	Female	Conenital kyphoscoliosis	PIF and deformity correction	Prof. S Rajasekaran	Observer
92	18.12.21	41	Female	L5/S1 PID	L5/S1 microdiscectomy	Dr A P Shetty	Observer
93	18.12.21	11	Male	NF type I Dystrophic scoliosis	PID and deformity correction	Dr A P Shetty	Assisted
94	18.12.21	49	Male	L4/5 Stenosis with right radiculopathy	L4/5 Microdecompression	Dr A P Shetty	Observer



Asia Pacific Spine Society (APSS)

(Spine Section of APOA)

95	18.12.21	70	Female	L5 compression fracture	L5 Vertebroplasty	Dr A P Shetty	Observer
96	18.12.21	76	Male	L4/5 Spondylodiscitis with sacralised L5	L3- pelvic fixation, decompression and debridement	Dr A P Shetty	Observer
97	18.12.21	49	Female	L4/5 grade 3 lytic spondylolisthesis	L4/5 TLIF	Dr A P Shetty	Assisted
98	18.12.21	32	Female	Multilevel tubercular spondylodiscitis with T8-T10 epidural abscess	Decompression, debridement and posterior instrumented fusion	Dr A P Shetty	Observer
99	18.12.21	21	Female	T12-L1 AO B2 injury	Posterior instrumented fixation	Dr A P Shetty	Observer
100	18.12.21	34	Female	T3-6 spondylodiscitis with paraplegia	Posterior instrumented fusion and biopsy	Dr A P Shetty	Assisted
101	20.12.21	53	Male	L4/5 Grade I degenerative spondylolisthesis	L4/5 TLIF	Dr Rishi Kanna	Observer
102	20.12.21	34	Male	L2-3 AO B2 injury	Posterior fixation	Dr Rishi Kanna	Observer
103	20.12.21	61	Male	T7/8 spondylodiscitis	Posterior instrumented fixation, decompression and debridement	Dr Rishi Kanna	Assisted
104	21.12.21	61	Male	L4/5 PID	L4/5 MLD	Dr Rishi Kanna	Observer
105	21.12.21	71	Male	L4/5 PID with CES	L4/5 Microdecompression	Dr Rishi Kanna	Observer
106	21.12.21	53	Male	C3-7 OPLL	C3-C7 laminectomy with fusion	Dr Rishi Kanna	Observer
107	21.12.21	19	Male	L5/S1 Dysplastic spondylolisthesis	L5/S1 TLIF	Dr Rishi Kanna	Assisted
108	23.12.21	2	Male	Congenital muscular torticollis	Right sided unipolar release	Dr Rishi Kanna	Observer
109	23.12.21	42	Female	L4/5 and L5/S1 PID	L4-S1 MLD	Dr Rishi Kanna	Observer



Asia Pacific Spine Society (APSS)

(Spine Section of APOA)

110	23.12.21	60	Male	L4/5 Stenosis with right radiculopathy	L4/5 TLIF	Dr Rishi Kanna	Observer
111	23.12.21	71	Male	L4/5 PID with CES	L4/5 MLD	Dr Rishi Kanna	Assisted
112	23.12.21	41	Male	T10-11 OLF	Decompression	Dr Rishi Kanna	Assisted
113	23.12.21	53	Male	L4/5 PID with facet cyst	L4/5 TLIF left	Dr Rishi Kanna	Observer
114	23.12.21	50	Female	L5/S1 PID	L5/S1 MLD	Dr Rishi Kanna	Observer
115	23.12.21	69	Female	L3/4 PID with L4/5 Instability	L3-5 TLIF	Dr Rishi Kanna	Observer
116	23.12.21	30	Male	L4/5 and L5/S1 PID	L4/5 and L5/S1 MLD	Dr Rishi Kanna	Observer
117	23.12.21	48	Male	C5 IDEM ? Schwanoma	Tumour excision	Dr Murali	Observer

At last, once again I will like to thank APSS, Jennifer, Prof. Dr S Rajasekaran sir, all the Faculty members and Fellows of Ganga Spine Department, Mr. Mohan and my co travelling fellows from Bangladesh Dr Sarwar Jahan and Dr Asraf ul Matin for all learning opportunities, sharing of knowledge and beautiful memories!

