

APSS - GANGA HOSPITAL FELLOWSHIP REPORT

3rd December to 24th December, 2021

Fellow - Dr Md Sarwar Jahan
MBBS, FCPS (Orthopedics)
CONSULTANT (Orthopedics)
NITOR, Dhaka, Bangladesh

Host - Prof. S. Rajasekaran, Ganga Hospital, Coimbatore, India.



Pic 1: Prof S Rajasekaran

The Asia-pacific spine society (APSS) Ganga Hospital spine fellowship 2020 was scheduled for me from 3rd December to 24th December 2021 at Ganga hospital, Coimbatore, India under the mentorship of Prof S. Rajasekaran. I was indeed delighted to had the 3 weeks APSS Ganga Hospital Spine Fellowship 2020. I was privileged having unique opportunity to learn the tips, tricks and technique from the masters in the ever evolving field of spine surgery. APSS arranged for me a very good opportunity to know different concept, philosophy, use of modern technology in spine surgery in a world famous South Indian Big Hospital.




Pic 2 : With Prof S Rajasekaran



Pic 3 : Infront of Ganga Hospital

My fellowship schedule and all the official formalities were very nicely arranged by APSS. Heartfelt thanks to the coordinator Jennifer Matthew for arranging such a hassle free fellowship program. I reached Coimbatore airport via Chennai International airport on 2/12/2021 as per schedule. Everything had been arranged nicely before my arrival by Host. A driver from Ganga hospital received me at airport & took me to the Ganga guest house. The Guest house was comfortable which was near the Ganga hospital. I was pleased of that accommodation.

On that very first day morning Prof S Rajasekaran introduced himself and his entire spine team and discussed with me about my interests and expectations. He briefed the details about Ganga hospital. There were 2 more spine fellows at that time schedule, one from APSS travelling fellowship program & another one from AOSPINE.

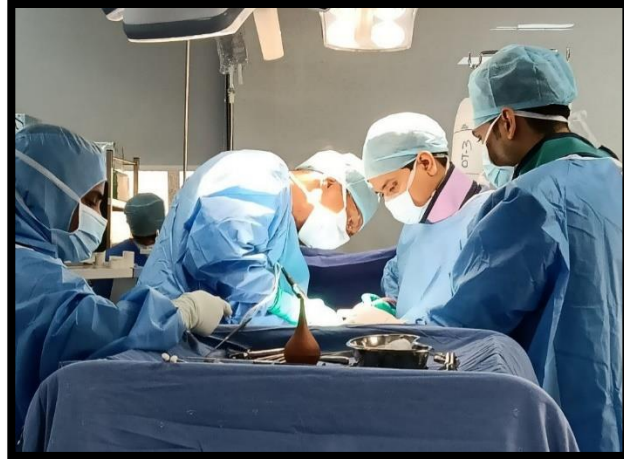

Pic 4: With the Ganga Spine team

During my period of fellowship, I participated in different surgical procedure. Huge number of surgeries were done there everyday. I had many more good experiences there in Ganga Hospital. There almost all surgeries performed with help of high resolution microscope. This was new for me. I had never use microscope before. Here Prof S Rajasekaran sir had arranged a hands on workshop on microscope that was a new experience for me where I was oriented on microscopic disc surgery.


Prof S Rajasekaran is a wonderful personality. He was always smiling and encouraging and performed surgeries in an artistic fashion under the microscope. Sir is excellent in posterior cervical spine surgeries & complicated scoliosis surgeries.

Prof S Rajasekaran Sir was 8th wonder of the world to me. He was so caring that in every steps of my training period was being observed by himself. He used to show what procedure was he doing. He opened new windows for me by arranging hands on workshops on High speed barr & microscope orientation.



Pic 5: Scrubbing with Prof Rajasekaran

Prof Rajasekaran is creating knowledge & making younger people interested in the field of research. He arranged another workshop of Next Genom Sequencing (NGS) where all eminent scientists presented their thinking & future plans. Prof Rajasekaran is now hunting the bacteria in every cell of human body that are responsible for the disease condition, & also trying to solving the problems by modifying bacterial cross talking. I was really astonished that how can a man be so excellent in thinking, knowledge creating & implementing the dreams he dreamed.



Pic 6 : Workshop on Microscopic Spine Surgery & High Speed Barr

Dr Ajoy Prasad Shetty is a skilfull surgeon and performed surgeries mathematically and flawless. He is a master class spine surgeon with good friendly attitude. I was lucky to see beautiful demonstration of state of the art of spinal operations from him. Dr Rishi Mugesh Kanna is another fine tuned spine surgeon I have ever seen. As an APSS fellow, I was allowed to scrub in and join at the table for assistance in some of the cases of spine surgery. I had the oppportunity to assist Prof Rajasekaran sir, Dr Ajoy Shetty sir & Dr Rishi sir during my fellowship program.

There was clinical presentation, pre-op and post-op case presentation & surgical audit presentation by the residents followed by discussion as per schedule. I learned a lot to know how to make decision for every case and what the goal is and reasons behind it. I learned not only the technique but also the idea of management also.



Pic 7 : Sharing experiences

After a wonderful schedule I was requested to share my experience in front of the Ganga of spine surgery team. I was awarded the fellowship certificate by the president of APSS , Prof S Rajasekaran Sir. it is a matter of honour & pride to receive certificate from the esteemed personality.



Pic 8 : Receiving Certificate

Undoubtedly, the spine centre in Ganga hospital is an ideal place for fellowship and I would like to recommend every spine surgeon should come here once in his lifetime.

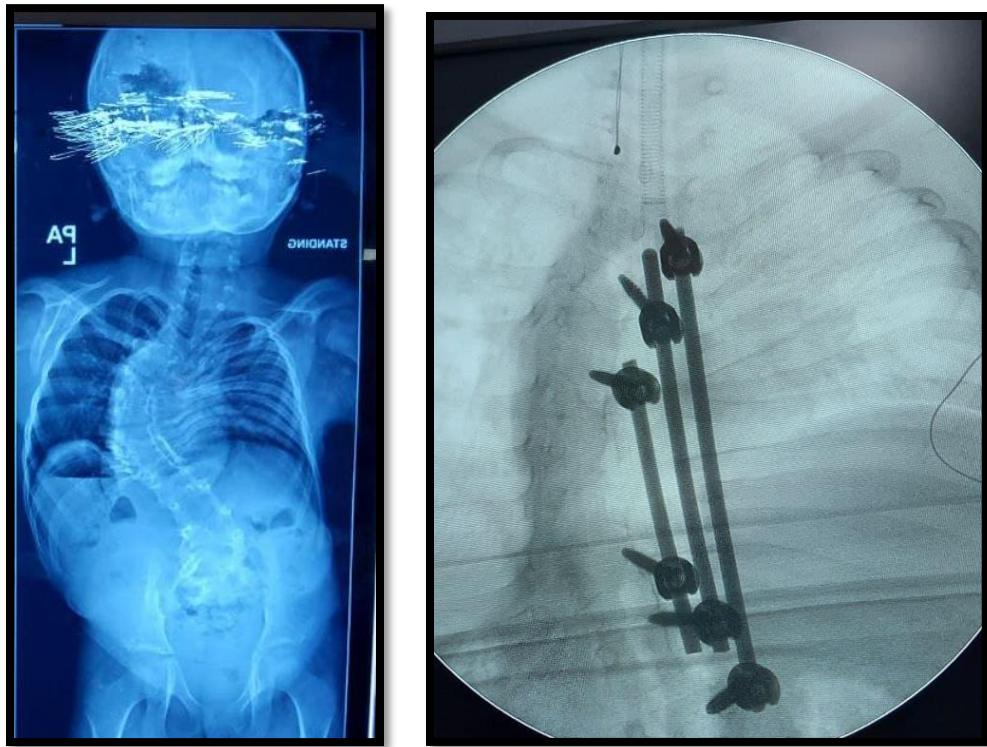
I am grateful to Prof S Rajasekaran Sir and entire spine team of ganga hospital for their cordial hospitality.

Finally I would like to thanks APSS for selecting me for the fellowship program and giving me this unique opportunity.

Case 1 : Scoliosis

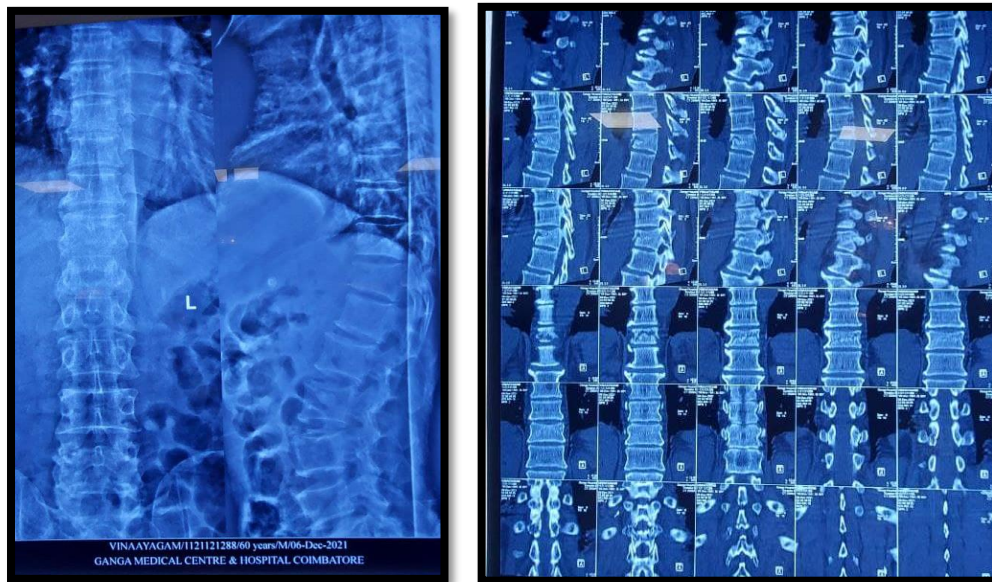


Pic 9 : Pre & per operative

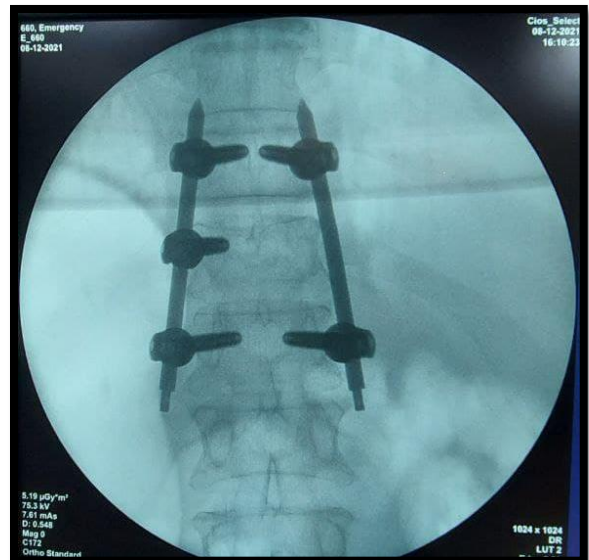
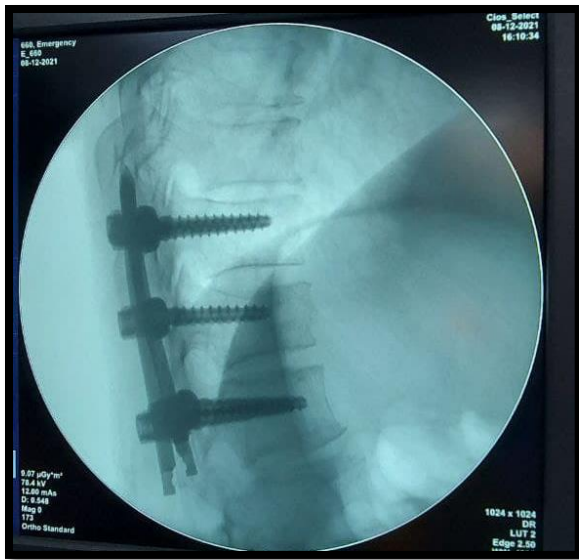


Pic 10 : Scoliosis Before & after correction

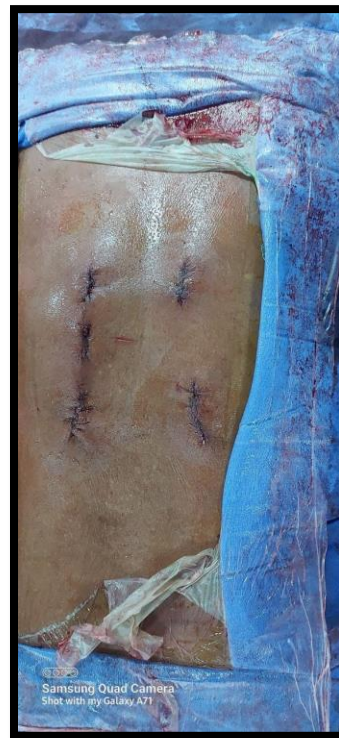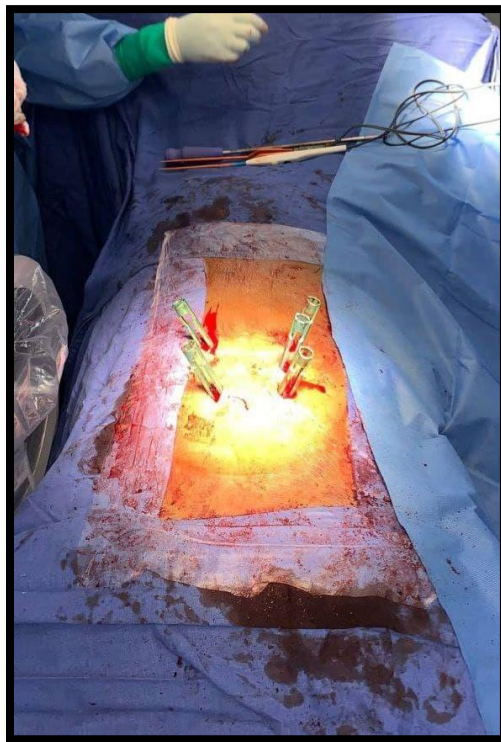Case 2 : MIS in Spine fracture



Pic 11 : D12 Compression fracture – Pre operative



Pic 12 : D12 Compression fracture – Post operative



Pic 13 : D12 Compression fracture – Per operative

Spine Log Book

No	Date	Name Age/ Sex	Diagnosis	Procedure	Surgeon	Role
1	3rd December	Kasilingam 43y, M	T6/7 Extradural N Sheath Tumour(Schwannoma)	Excision Biopsy	Dr. S. Rajasekeran	Observer
2		Praveena 37y,F	Type2 Hangman fracture with Odontoid fracture	Anterior Screw fixation	Dr. S. Rajasekeran	Observer
3		Abibur, 29y/M	L3/4L4/5 Disc Prolapse Rt Radiculopathy,L4/5	Microdiscectomy	Dr. Ajoy P. Shetty	Observer
4	4th December	Venkateshan, 50y/M	DISH with C7 AO Type B3 Injury;C7T1	ACDF with AC Plating	Dr. Ajoy P. Shetty	Observer
5		Hemanth 45y/M	L4/5 Gr3 Lytic Listhesis with BL Radiculopathy;	L4/5 Fusion	Dr. Ajoy P. Shetty	Observer
6		Dhanalaxmi 33y/F	SED wihThoracolumbar Kyphosis & hip dysplasia;	PSO & Fusion	Dr. S. Rajasekeran	Assistant
7	6th December	Marisamy, 28 y/F	L1L2 AO A4 Injury with normal neurology	,L3-L5 stabilization	Dr. Ajoy P. Shetty	Observer
8		Manukaran 52y/M	DISH with Tendem Stenosis C5-C6 DOC L4/5 deg.Listhesis	ACDF	Dr. Rishi M. Kanna	Observer
9		Chinnadurat, 32y/M	L1L2 AO A4 Injury with normal neurology ,	L3-L5 stabilization	Dr. Rishi M. Kanna	Observer
10	7th December	Vimala, 62y/F	Atlanto Occipital Assimilation,basal invagination;	OC Fusion	Dr. S. Rajasekeran	Observer
11		Kodhus, 14y/M	AS,Thoracolumbar kyphoscoliosis;	PIS, PSO,Correction,Fusion	Dr. S. Rajasekeran	Observer
12		Satheesh, 47y/M	C4/5,C6/7 DOC,Nurick3 Myelopathy,	ACDF C4/5 &C6/7	Dr. Rishi M. Kanna	Assistant
13		Vanaja, 65y/F	D4 Pathological Collapse	PIS with biopsy & Decopression	Dr. Rishi M. Kanna	Observer
14	8th December	Sundararajan, 56y/M	C5/6,C7 Segmental OPLL, C6/7 DOC;	C6 Corpectomy C567 ACDF	Dr. Ajoy P. Shetty	Observer
15		Kannan, 35y/M	Lumbar Canal Stenosis, L3/4 DOC,	Microdiscectomy L3/4	Dr. Rishi M. Kanna	Assistant
16		Chinnadurat 36 y/M	L1-L2 B2,L1L2 A4 Injury;	Posterior Instrumental Stabilization	Dr. Rishi M. Kanna	Observer
17	9th December	Jeevankumar 64y/M	C3C4,C5C6 DOC,Nurick2 Myelopathy;	C3-C4 C5C6 ACDF	Dr. Ajoy P. Shetty	Observer
18		Kobitha, 12y/F	Cong Lt Thoracic Scoliosis,Escobar Synd,	Concave osteotomy	Dr. S. Rajasekeran	Observer

19		Shahar, 23y/M	L5S1 Disc Prolapse with Radiculopathy	Endoscopic discectomy	Dr. Ajoy P. Shetty	Observer
20		Mohammad Ali 34y/M	L4/5 Rec Disc Prolapse B/L Radiculopathy	L4/5 Rev Discectomy	Dr. Ajoy P. Shetty	Observer
21	10th December	Konjikadiyumma 53y/M	Deg Cervical kyphosis, C6/7 Retrolisthesis, L1 OVCF,	C5/6 ACDF	Dr. S. Rajasekaran	Assistant
22		Vinayagam, 45y/F	T10-T11, B2 T11 A3 injury n neurology;	post MIS T10-T12	Dr. Ajoy P. Shetty	Observer
23		Santosh, 65y/M	C1 Burst #Type2 Odontoid fracture ASIA -A;	Temp O-C Fixation	Dr. Rishi M. Kanna	Observer
24	11th December	Sugavashi, 50y/F	C5-C6, C4-C5 DOC Nurick 1 Myelopathy;	C4/5, C5/6 ACDF	Dr. Rishi M. Kanna	Assistant
25		Ashwin, 25y/M	L5S1 Disc Prolapse Lt Radiculopathy;	L5S1 Endoscopic Discecto	Dr. Rishi M. Kanna	Observer
26		Krishnaveni 55y/F	L5 IDEM(Myxopapillary Ependymoma);	Excision Biopsy	Dr. S. Rajasekaran	Observer
27	13th December	Mallika, 45y/F	T2 Level Schwannoma;	Tumour Excision & Biopsy	Dr. Ajoy P. Shetty	Observer
28		Babu, 35y/M	L4-L5 Disc Prolapse Lt Radiculopathy,	Microscopic Discectomy	Dr. Ajoy P. Shetty	Observer
29		Shradha, 45y/F	L4-L5, L5-S1 Deg. Listhesis;	L4-L5 Decompression & Fusion	Dr. Ajoy P. Shetty	Observer
30	14th December	Anil Kumar, 65y/M	C3-C4 OPLL, Comp. Myelopathy;	C3-C4 ACDF	Dr. S. Rajasekaran	Assistant
31		Avijit, 57y/M	C4-C5 Disc prolapse Rt Radiculopathy;	C4-C5 ACDF	Dr. Ajoy P. Shetty	Observer
32		Mohammed, 32y/M	L4-L5 Disc prolapse with Rt Radiculopathy;	SNRB L5	Dr. Ajoy P. Shetty	Observer
33	15th December	Samreet, 15y/M	AIS Lenke Type 3C;	T4-L3 PIS with Deformity Correction	Dr. S. Rajasekaran	Assistant
34		Kadeeja, 67y/F	Odontoid # non union;	Foramen magnum decompression OC fusion	Dr. S. Rajasekaran	Observer
35		Thamban, 52y/M	C3/4/5/6/7 DOC N4 Myelopathy;	Lateral mass fixation laminectomy	Dr. Rishi M. Kanna	Observer
36	16th December	Chinnaponnu 38y/M	L4-5 Disc prolapse with Lt Radiculopathy;	L4/5 Microdiscectomy	Dr. Rishi M. Kanna	Observer
37		Anujith, 42y/M	C5 Pedicle Osteoid Osteoma (Rt) Radiculopathy;	Excision Biop	Dr. Ajoy P. Shetty	Observer
38		Kandasamy, 37y/M	C6/7 DOC With Cord oedema with N2 Myelopathy;	C6-C7 ACDF	Dr. Rishi M. Kanna	Observer
39	17th December	Booblan, 52y/M	C5/6, C6/7 Disc Prolapse Rt Radiculopathy,	C6/7, C5/6 ACDF	Dr. Ajoy P. Shetty	Assistant
40		Rabindra, 55y/M	DISH C5/6 OPLL, C2-C7 DOC N3 Myelopathy,	C3-C7 PIS, Laminectomy	Dr. S. Rajasekaran	Observer
41		Mohamed,	C3-C7 DOC N1	C3-C7 Pedicle screw	Dr. S.	Observer

		64y/M	Myelopathy;	fixation decompre	Rajasekaran	
42	18th December	Thirupathy, 46y/M	L3-L5 Canal Stenosis B/L Radiculopathy,	L3-L5 Microdecompress	Dr. Ajoy P. Shetty	Assistant
43		Kirthick, 12y/M	L4 Inferior End Plate Avulsion, Canal Stenosis;	L4/5 Microdis	Dr. Ajoy P. Shetty	Observer
44		Muthusamy, 26y/M	T12L1 AO B2 Injury, L1 A3 Injury, N Neurology;	PIS ,Decompress	Dr. Rishi M. Kanna	Observer
45	20th December	Prashant, 25y/M	L5S1 Disc Prolapse with Hypoplastic L5;	L5S1 Decompression	Dr. S. Rajasekaran	Observer
46		Mahboob, 45y/M	L4L5 Gr 1 Listhesis with Stenosis ;	L45 Decompression Fusion	Dr. Rishi M. Kanna	Observer
47		Zunairah, 42y/F	T10-l2 OLF L2L3 ASD;	T10- Iliac PIS ,Fusion	Dr. Ajoy P. Shetty	Observer
48	21th December	Satish, 65y/M	Rec. Lt Paraspinal Tumour T10-T11;	Excission Biopsy	Dr. Ajoy P. Shetty	Assistant
49		Lokanathan 33y/M	Post Traumatic # L1,AO A3 N Neurology	PIS	Dr. Ajoy P. Shetty	Observer
50		Rushby, 58/F	C2-C7 OPLL N Myelopathy;	C2-C7 Pedicle screw fixation lamine	Dr. S. Rajasekaran	Observer
51	22th December	Aneeta, 13y/F	Cong.D/L Kyphoscoliosis;	Posterior Instrumented deformity corr	Dr. S. Rajasekaran	Assistant
52		Umesh, 15y/M	NF Type1,Dystrophic left thoracic Scoliosis;	T2-L3 PIS correc	Dr. Ajoy P. Shetty	Observer
53		Radhika, 25y/M	L5S1 Discogenic stenosis,BL Radiculopathy;	L5S1 Microdissecto	Dr. Ajoy P. Shetty	Observer
54		Revathy, 28y/F	T78 Spondylodiscitis T9-10 Disc Prolapse;	PIS T5-10 e Decompr	Dr. Rishi M. Kanna	Observer
55	23th December	Karthik, 25y/M	L23 AO B2 Injury N.Neurology;	Posterior Instrumented Stabili	Dr. Rishi	Observer
56		Vijoy, 45y/M	L4L5 Gr 1 Deg Listhesis	L45 Decompression and Fusion	Dr. Rishi M. Kanna	Assistant
57		Usman, 38y/M	L45 Disc Prolapse with Lt Radiculopathy,	L4L5 Microdissectomy	Dr.Rishi M. Kanna	Observer
58	24th December	Pravakaran, 56y/M	C3-C7 DOC with OPLL,N2 Myelopathy,	Post Instrumented laminect	Dr.Rishi M. Kanna	Observer
59		Akbar, 46y/M	L5S1 Gr1 Dysplastic Listhesis BL Radiculopathy;	L5S1 Fusion d	Dr.Rishi M. Kanna	Observer