

# APSS Medtronic Spine Fellowship

**Duration: 11<sup>th</sup> March 2019 to 8<sup>th</sup> June 2019**

Fellow:

Dr Nirmal D Patil

MBBS MS (Ortho) DNB (Ortho) MRCS (Eng) MNAMS

Guide:

Prof. Kuniyoshi Abumi

MD

Professor Emeritus, Hokkaido University

Director and Vice President, Sapporo Orthopaedic Hospital,  
Centre for Spinal Disorders Sapporo, 060-8638 Japan

Centres visited:

Hokkaido University Graduate School of Medicine, Sapporo  
&

Affiliated hospitals

- (1) Sapporo Orthopaedic Hospital, Centre for Spinal Disorders, Sapporo.
- (2) Spinal Cord Injury Centre, Hokkaido Chuo Rosai Hospital, Bibai.
- (3) Eniwa Hospital, Eniwa.
- (4) Hokkaido Orthopaedic Surgery Memorial Hospital, Sapporo
- (5) Hokkaido Medical Centre, Sapporo
- (6) Hokkaido University Hospital, Sapporo

## **Introduction**

First of all, I would like to thank Asia Pacific Spine Society (APSS) for awarding me this fellowship under Prof Kuniyoshi Abumi. The APSS arranged the airline tickets and accommodation. Jenny Wong and the APSS have been very well organised with the schedule for the fellowship. I arrived in Sapporo on 11th March 2019. Prof Abumi was kind enough to send his personnel to receive me at the airport. He even arranged basic daily utilities including Wifi so that I would not struggle in the initial days. I stayed at Cesar Kotoni apartment in Sapporo. The room was clean and comfortable with a lot of restaurants and mini markets around. The apartment was equipped with all the basic cooking equipment. Immediately I was taken to Sapporo Orthopedic Hospital and was greeted by Prof Abumi. Following a basic introduction I was allowed to scrub in with him for the Lumbar L5-S1 TLIF case. After the case, Prof Abumi invited me for dinner. It was a pleasure interacting with him. It amazes me how a world famous surgeon is so down to earth.

Subsequently I visited hospitals all around the Hokkaido Island of Japan. Wherever there was a good spine surgery, Prof Abumi scheduled my travel to that hospital. Prof Abumi was kind enough to arrange for my travel to far away hospitals. In these 3 months I got to see a variety of surgeries, ranging from basic degenerative to scoliosis and cranio-vertebral spine surgeries. I saw a novel technique of Cortical Bone trajectory screws free hand and using 3D template. I have learnt the techniques for Laminoplasty and Cervical Pedicle screw fixation and I am confident that I can start utilising all these in my practice. Prof Abumi arranged for me to attend the JSSR 2019 in Yokohama. I interacted with great Japanese Spine surgeons and other surgeons from around the world.

I would like to thank Prof K Abumi, Dr Takeuchi and Dr Haba of the Sapporo Orthopedic Hospital, Dr Oda, Dr Takeuchi, Dr Oshima, Dr Fujiya and Dr Suzuki of Hokkaido Orthopedic Memorial Hospital; Dr Abey of Eniwa hospital, Dr Suda of Spinal Cord Injury centre and Dr Sudo of Hokkaido University Hospital for taking the time to answer all my queries regarding the indications and techniques of spine surgery. To put all together it was a very memorable experience. Asia Pacific Spine Society has taken a great initiative to broaden the horizons of all young spine surgeons and metamorphose them into world class surgeons.

## **Log Book:**

No	Date	Age	Sex	Diagnosis	Plan	Surgeon	My role	Hospital
1	11/03	51	M	L5-S1 lytic spondylolisthesis with L4-L5 LCS	L5-S1 TLIF and L4-L5 decompression	Prof K. Abumi	Assistant	Sapporo Orthopaedic Hospital
2	12/03	75	M	L2-L3 Stenosis with L5-S1 Spondylolisthesis and Stenosis	L2-L3 Central Decompression, L5-S1 TLIF, Wiltse approach	Dr M. Suzuki	Assistant	Hokkaido Orthopaedic Surgery Memorial Hospital
3	12/03	60	M	L5-S1 lytic spondylolisthesis with foraminal stenosis	L5-S1 TLIF	Dr M. Suzuki	Assistant	Hokkaido Orthopaedic Surgery Memorial Hospital
4	13/03	60	M	L5-S1 lytic spondylolisthesis	L5-S1 TLIF	Dr K. Suda	Observer	Spinal Cord Injury Centre, Bibai
5	13/03	70	M	Post Laminectomy (C3-C6) C6 Radiculopathy	C4-C6 Hybrid Lateral Mass -Pedicule Screw Construct and C6 foraminotomy	Dr K. Suda	Observer	Spinal Cord Injury Centre, Bibai
6	13/03	76	M	L5-S1 Degenerative Spondylolisthesis with LCS	L4-S1 Fixation, L5-S1 TLIF	Dr K. Suda	Observer	Spinal Cord Injury Centre, Bibai
7	13/03	84	F	Osteoporotic fracture D11	Balloon Kyphoplasty	Dr K. Suda	Observer	Spinal Cord Injury Centre, Bibai
8	14/03	67	M	L4-L5 Lumbar Canal Stenosis	Inter-Laminar decompression	Dr S. Oshima	Assistant	Hokkaido Orthopaedic Surgery Memorial Hospital
9	18/03	25	F	Lumbar scoliosis with anterior bony void due to neurofibromatosis with dural ectasia	Posterolateral fusion T9-L1 and L4-S1 + SI screw instrumentation	Dr K. Abumi	Assistant	Sapporo Orthopaedic Hospital
10	19/03	20	F	AIS Lenke type 6	Scoliosis correction with pedicle screws	Dr M. Ito	Observer	Hokkaido Medical Centre
11	20/03	50	F	OLF with degenerative scoliosis	OLIF L2-L5 with PLF L1-L5 with OLF decompression L1-L2	Dr Takeachi	Assistant	Hokkaido Orthopaedic Surgery Memorial Hospital
12	20/03	70	F	L2-L3 disc prolapse (Adjacent segment) in a case of L3-L4 Anterior fusion	PLIF L2-L3	Dr Fujiya	Assistant	Hokkaido Orthopaedic Surgery Memorial Hospital
13	22/03	55	F	Postlaminectomy (C3-C5) persisting C5 radiculopathy and C6-C7 myelopathy	Pedicule screw C4-C6 and C5 Left foraminotomy	Dr K. Abumi	Assistant	Sapporo Orthopaedic Hospital
14	25/03	60	M	Degenerative scoliosis with LCS and Left sciatica	L2-L5 posterior decompression	Dr T. Kobaku	Assistant	Eniwa Hospital
15	26/03	11	F	Lenke type 1 A N AIS	T5-L1 instrumentation and dual rod derotation	Dr Sudo	Observer	Hokkaido University Hospital
16	27/03	65	M	Cervical spondylotic myelopathy C3-C6	Laminoplasty C3-C6	Dr Abe	Assistant	Eniwa Hospital
17	28/03	60	F	Left sciatica L2-L3 acute onset	Discectomy fenestration	Dr Oda	Assistant	Hokkaido Orthopaedic Surgery Memorial Hospital
18	28/03	65	F	OLF repeat stenosis at L2-L3	OLIF L2-L3	DR Yoshie	Assistant	Hokkaido Orthopaedic Surgery Memorial Hospital
19	29/03	69	M	LCS due to lytic listhesis L4-L5 L5-S1	PLIF L3-S1	Dr K. Abumi	Assistant	Sapporo Orthopaedic Hospital
20	01/04	85	F	LCS L3-L4, L4-L5	Posterior decompression	Dr K. Abumi	Assistant	Sapporo Orthopaedic Hospital
21	01/04	60	M	C4, C5 Segmental OPLL	Laminoplasty C3-C6	Dr K. Abumi	Assistant	Sapporo Orthopaedic Hospital
22	02/04	60	M	Cervical myelopathy due to OPLL c4-c5	T saw Laminoplasty C3-C6	Dr Suzuki	Assistant	Hokkaido Orthopaedic Surgery Memorial Hospital

23	02/04	80	F	Myelopathy due to Adjacent segment at L1	Decompression and PLF	Dr Suzuki	Assistant	Hokkaido Orthopaedic Surgery Memorial Hospital
24	03/04	80	M	Spondylotic myelopathy with instability C4-C5	Laminoplasty double door	Dr K. Suda	Observer	Spinal Cord Injury Centre, Bibai
25	03/04	83	M	Old L2 pedicle fracture with Degenerative kyphotic deformity D12	Long segment fixation	Dr K. Suda	Observer	Spinal Cord Injury Centre, Bibai
26	03/04	30	M	L5-S1 PIVD	Micro-discectomy	Dr K. Suda	Observer	Spinal Cord Injury Centre, Bibai
27	04/04	30	F	Neglected AIS Lenke type 5	T9-Pelvis fusion	Dr Abe	Assistant	Eniwa Hospital
28	05/04	40	M	L4-L5 lytic listhesis	L4-L5 PLIF	Dr Oda	Assistant	Hokkaido Orthopaedic Surgery Memorial Hospital
29	05/04	60	F	C4-C6 Spondylotic myelopathy	C3-C6 T saw Laminoplasty	Dr Oda	Assistant	Hokkaido Orthopaedic Surgery Memorial Hospital
30	08/04	60	M	Degenerative Scoliosis L2-L5 with previous laminectomy done with LCS	L3-L5 Decompression	Dr K Abumi	Assistant	Sapporo Orthopaedic Hospital
31	08/04	30	M	C6 radiculopathy due to calcified C5-C6 disc	C5-C6 ACDF stand alone	Dr K Abumi	Observer	Sapporo Orthopaedic Hospital
32	09/04	65	F	C4-C6 Spondylotic myelopathy	Double door Laminoplasty C3-C6	Dr Suzuki	Assistant	Hokkaido Orthopaedic Surgery Memorial Hospital
33	09/04	67	M	C4-C6 Spondylotic myelopathy	Double door Laminoplasty C3-C6	Dr Suzuki	Assistant	Hokkaido Orthopaedic Surgery Memorial Hospital
34	10/04	50	M	Finger drop left side with C6-C7 foraminal stenosis	C6-T1 fixation and C6-C7 foraminotomy	Dr K. Suda	Observer	Spinal Cord Injury Centre, Bibai
35	10/04	65	M	Degenerative scoliosis with LCS at L2-L3	L2-L3 TLIF	Dr K. Suda	Observer	Spinal Cord Injury Centre, Bibai
36	10/04	34	M	L5-S1 PIVD	Micro-discectomy	Dr K. Suda	Observer	Spinal Cord Injury Centre, Bibai
37	10/04	70	F	Osteoporotic Pelvic ring # with non-union Sacral H fracture	Iliac screw BL to stabilise the ring	Dr K. Suda	Observer	Spinal Cord Injury Centre, Bibai
38	11/04	68	M	C4-C6 Spondylotic myelopathy	Double door Laminoplasty C4-C6	Dr S. Oshima	Assistant	Hokkaido Orthopaedic Surgery Memorial Hospital
39	15/04	63	M	L4-S1 LCS	Decompression	Dr Hyakumachi	Assistant	Eniwa hospital
40	15/04	40	M	PLD herniation L4-L5	Microdiscectomy	Dr Hyakumachi	Assistant	Eniwa hospital
41	15/04	75	F	L4-L5 LCS with foraminal stenosis	L4-L5 TLIF	Dr Hyakumachi	Assistant	Eniwa hospital
42	16/04	18	F	Lenke type 5C AIS	T9-L3 instrumentation dual rod rotation	Dr Sudo	Observer	Hokkaido University Hospital
43	17/04	50	M	C4-C5 foraminal stenosis with C6 myelopathy	Foraminal decompression and laminoplasty C6	Dr Takeuchi	Assistant	Sapporo Orthopaedic Hospital.
44	22/04	67	F	Degenerative kyphoscoliosis	T9 to SI joint fixation, rod rotation and osteotomy ponte for deformity correction	Dr Abumi	Assistant	Sapporo Orthopaedic Hospital.
45	23/04	18	F	Lenke type 5C AIS	T9-L3 instrumentation dual rod rotation	Dr Sudo	Observer	Hokkaido University Hospital
46	24/04	50	M	C3-C6 OPLL	C3-C6 Laminoplasty and pedicle screw insertion	Dr Takeuchi	Assistant	Hokkaido Orthopaedic Surgery Memorial Hospital
47	24/04	45	M	Degenerative spondylolisthesis	PLIF L4-L5	Dr Takeuchi	Assistant	Hokkaido Orthopaedic Surgery Memorial Hospital
48	25/04	40	M	Posterior neck tumour excision	Neck tumour excision	Dr Abumi	Assistant	Sapporo Orthopaedic Hospital.

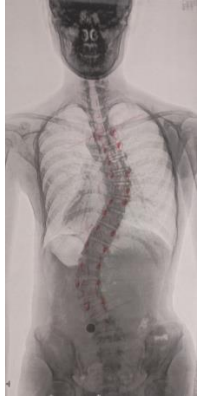49	25/04	55	M	PLIF L4-L5 with foraminal stenosis L4-L5 L5-S1	Revision L4-L5 , L5-S1 Foraminotomy	Dr Abumi	Assistant	Sapporo Orthopaedic Hospital.
50	26/04	65	F	Degenerative spondylolisthesis L4-L5	TLIF L4-L5	Dr Haba	Assistant	Sapporo Orthopaedic Hospital.
51	07/05	60	M	Adjacent segment L3-L4	TLIF L3-L4	Dr Haba	Assistant	Sapporo Orthopaedic Hospital.
52	07/05	55	M	Adjacent segment L2-L3	TLIF L2-L3	Dr Takeuchi	Assistant	Sapporo Orthopaedic Hospital.
53	08/05	50	M	C4-C6 spondylotic myelopathy	C4-C6 Double door Laminoplasty	Dr Takeuchi	Assistant	Hokkaido Orthopaedic Surgery Memorial Hospital
54	08/05	65	M	L3-L4 and L4-L5 degenerative LCS. Previously operated for L4-L5 disc with nucleotomy	PLIF L4-L5, L3-L4	Dr Takeuchi	Assistant	Hokkaido Orthopaedic Surgery Memorial Hospital
55	09/05	65	M	Degenerative spondylolisthesis with LCS	PLIF L4-L5	Dr Haba	Assistant	Sapporo Orthopaedic Hospital.
56	10/05	75	F	PJK with osteoporotic fracture D12 (PLF done L1-L2 previously)	Vertebroplasty and extension of fusion T10-L2	Dr Oda	Assistant	Hokkaido Orthopaedic Surgery Memorial Hospital
57	10/05	69	F	Degenerative scoliosis	TLIF L4-S1 with cortical bone trajectory screws with Posterior decompression L2-L4	Dr M. Suzuki	Assistant	Hokkaido Orthopaedic Surgery Memorial Hospital
58	10/05	68	M	CSM	Laminoplasty C3-C6	Dr M. Suzuki	Assistant	Hokkaido Orthopaedic Surgery Memorial Hospital
59	13/05	16	F	Lenke 5 C AIS	Deformity correction dual rod rotation T9 to L3	Dr K. Abumi/ Dr Abey	Assistant	Sapporo Orthopaedic Hospital.
60	13/05	85	F	Degenerative scoliosis with Lumbar canal stenosis L2-L5	Decompression L2- L5	Dr K Abumi	Assistant	Sapporo Orthopaedic Hospital.
61	14/05	50	F	Thoracic d12 schwannoma	Tumour excision	Dr Sudo	Observer	Hokkaido University Hospital
62	15/05	67	M	Degenerative spondylolisthesis with LCS	PLIF L4-L5	Dr Takeuchi	Assistant	Hokkaido Orthopaedic Surgery Memorial Hospital
64	16/05	68	F	ASD in a case of previously operated C0-C3 for RA instability	C3-T1 fix with domino C0-C3	Dr Oda	Assistant	Hokkaido Orthopaedic Surgery Memorial Hospital
65	16/05	60	F	AAD with C3-C4 instability in RA	C1-C4 fix	Dr K Abumi	Assistant	Sapporo Orthopaedic Hospital.
66	17/05	48	M	ASD L2-L3	PLF L2-L3	Dr M. Suzuki	Assistant	Hokkaido Orthopaedic Surgery Memorial Hospital
67	17/05	55	F	Myelopathy with congenital canal stenosis	Laminoplasty C3-C6	Dr M. Suzuki	Assistant	Hokkaido Orthopaedic Surgery Memorial Hospital
68	17/05	69	F	L1 Osteoporotic #	T11-L1 pedicle screw with sublaminar tape and PLF	Dr M. Suzuki	Assistant	Hokkaido Orthopaedic Surgery Memorial Hospital
69	20/05	68	M	ASD L2-L3	PLF L2-L3	Dr Haba	Assistant	Sapporo Orthopaedic Hospital.
70	20/05	45	M	Degenerative spondylolisthesis	PLIF L4-L5	Dr Haba	Assistant	Sapporo Orthopaedic Hospital.
71	21/05	16	F	Lenke type 3 AIS	T4-L3 PSF	Dr Sudo	Observer	Hokkaido University Hospital
72	22/05	76	F	C5-C6 MYELOPATHY	C3-C6 laminoplasty	Takeuchi	Assistant	Hokkaido Orthopaedic Surgery Memorial Hospital
73	22/05	68	F	Sacral H type fracture	L5- SI screw fixation	Takeuchi	Assistant	Hokkaido Orthopaedic Surgery Memorial Hospital
74	23/05	56	F	L4-L5 Spondylolisthesis	TLIF	Dr Sudo	Observer	Hokkaido University Hospital
75	23/05	15	F	Lenke 5 C AIS	DEFORMITY CORRECTION	Dr Sudo	Observer	Hokkaido University Hospital

76	24/05	72	M	L3-L4 L4-L5 LCS	TLIF L3-L4 L4-L5 with CBT screws	Dr Oda	Assistant	Hokkaido Orthopaedic Surgery Memorial Hospital
77	26/05	67	M	L4-L5 Spondylolisthesis	TLIF	Dr Oda	Assistant	Hokkaido Orthopaedic Surgery Memorial Hospital
78	27/05	45	F	Neurofibroma L2-L3	Anterior plus posterior corpectomy fibula strut grafting tumour excision and fixation	Dr Sudo	Observer	Hokkaido University Hospital
79	28/05	55	F	OPLL	Laminoplasty and C4-T1 Pedicle Screw fixation	Dr Oda	Observer	Hokkaido University Hospital
80	28/05	60	M	LCS L4-L5	PLIF	Dr Abumi	Assistant	Sapporo Orthopaedic Hospital.
81	03/06	65	F	Adult kyphotic deformity osteoporotic D12 #	T9 to L2 fixation and pontes osteotomy	Dr Abumi	Assistant	Sapporo Orthopaedic Hospital.
82	04/06	50	M	Prolapsed disc l4-l5 and lcs l5s1	Fusion L5-S1	Dr M. Suzuki	Assistant	Hokkaido Orthopaedic Surgery Memorial Hospital
83	05/06	75	F	Cervical Myelopathy	C3-C6 fixation pedicle screw	Dr K. Suda	Observer	Spinal Cord Injury Centre, Bibai
84	05/06	65	M	LCS L3-L4 L4-L5	TLIF L3-L4 L4-L5	Dr K. Suda	Observer	Spinal Cord Injury Centre, Bibai
85	05/06	60	M	SAPHO Syndrome	Transpedicular Bone Biopsy	Dr K. Suda	Observer	Spinal Cord Injury Centre, Bibai
86	05/06	65	M	DISH extension #	Percutaneous Pedicle Screw	Dr K. Suda	Observer	Spinal Cord Injury Centre, Bibai
87	05/06	87	M	C4-C5 Distraction extension injury	Posterior C4-C5 stabilisation	Dr K. Suda	Observer	Spinal Cord Injury Centre, Bibai
88	06/06	55	F	LCS L4-L5 with listhesis	MIS TLIF	Dr Oda	Assistant	Hokkaido Orthopaedic Surgery Memorial Hospital
89	06/06	68	M	Cervical Myelopathy due to OPLL	C3-C6 Laminoplasty with C4-C5 pedicle screw fixation	Dr Takeuchi	Assistant	Hokkaido Orthopaedic Surgery Memorial Hospital
90	07/06	45	M	L3-L4 degenerative stenosis with grade 1 listheiss	PLIF with CBT screws	Dr M. Suzuki	Assistant	Hokkaido Orthopaedic Surgery Memorial Hospital
91	07/06	75	F	Cervical Myelopathy due to OPLL	C3-C6 Laminoplasty	Dr M. Suzuki	Assistant	Hokkaido Orthopaedic Surgery Memorial Hospital

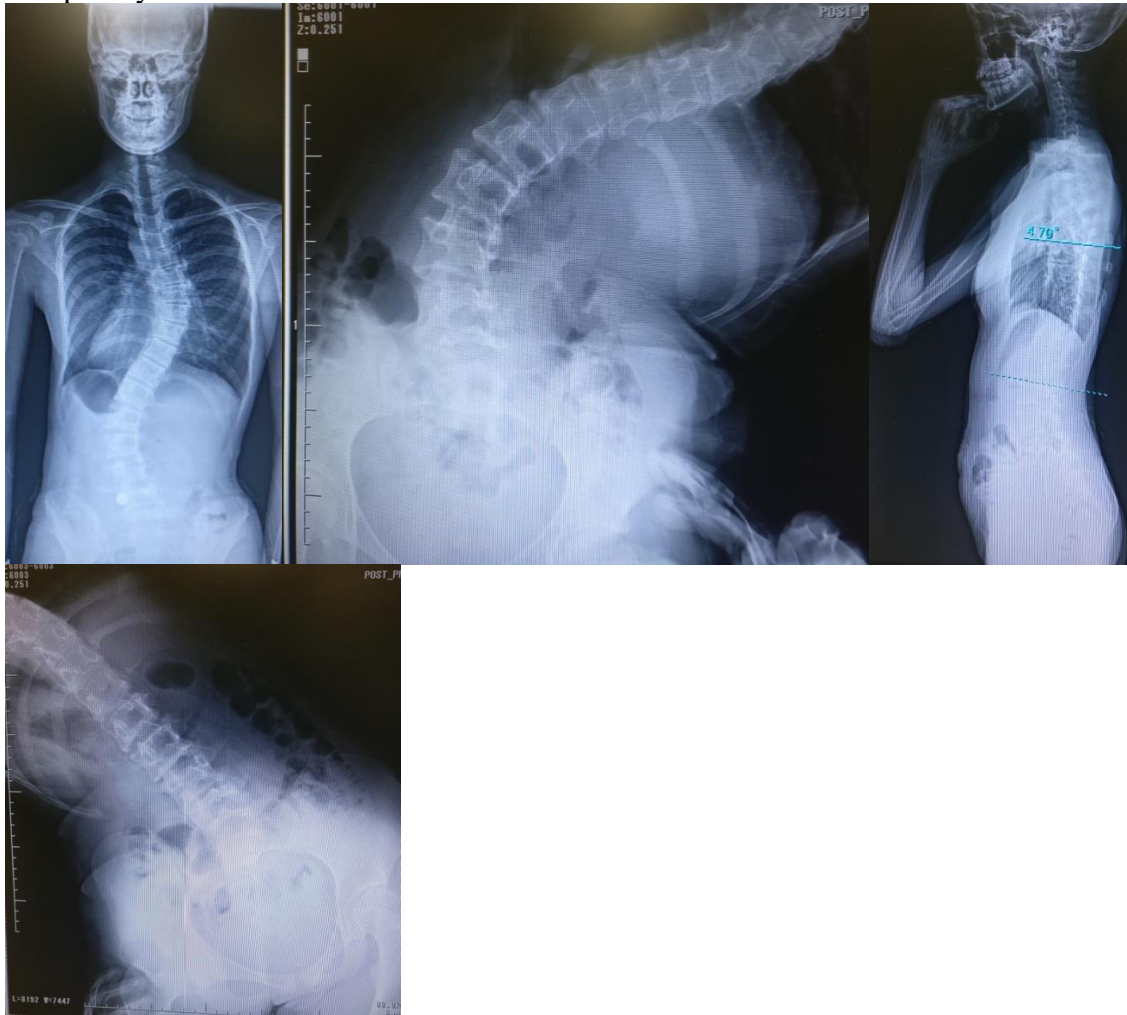
## Representative Cases

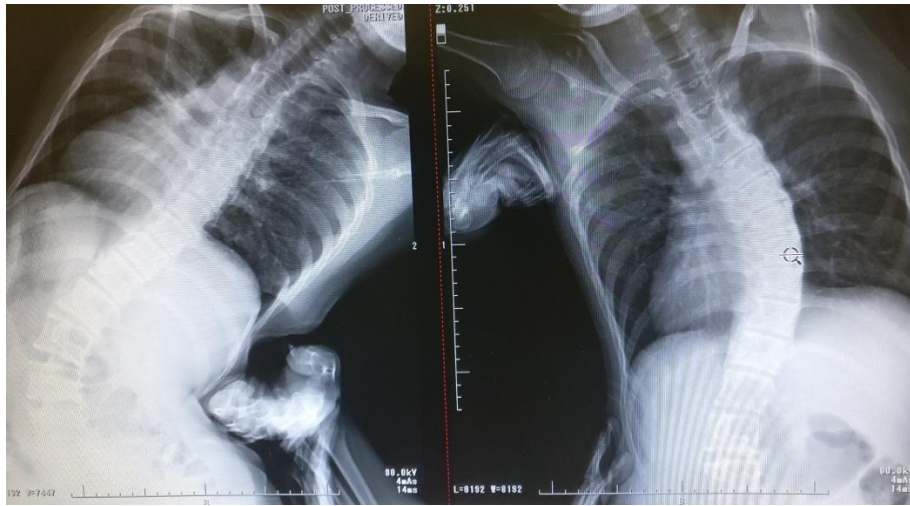
1. Lenke Type 3 C AIS in a 15 year old girl. Operated with the USS Medtronic system and dual rod rotation.

### A) Preop Planning

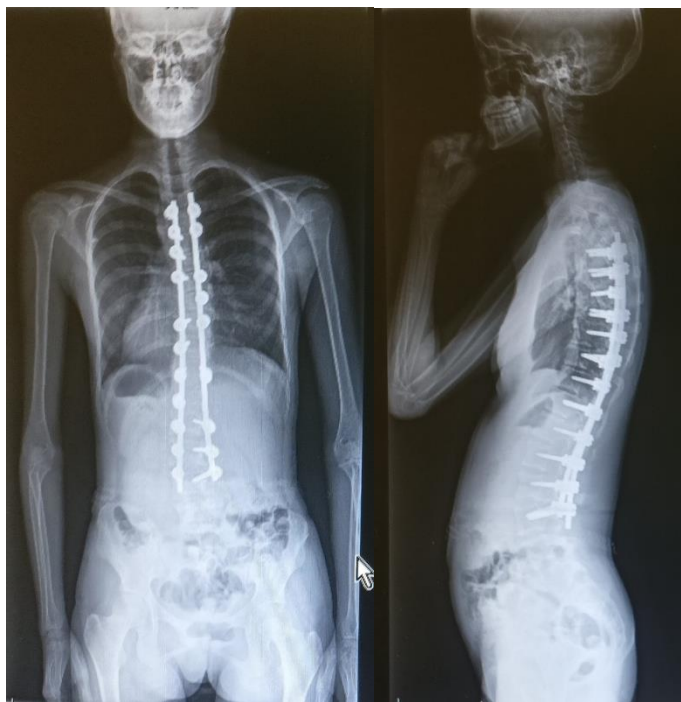

Preop Xrays



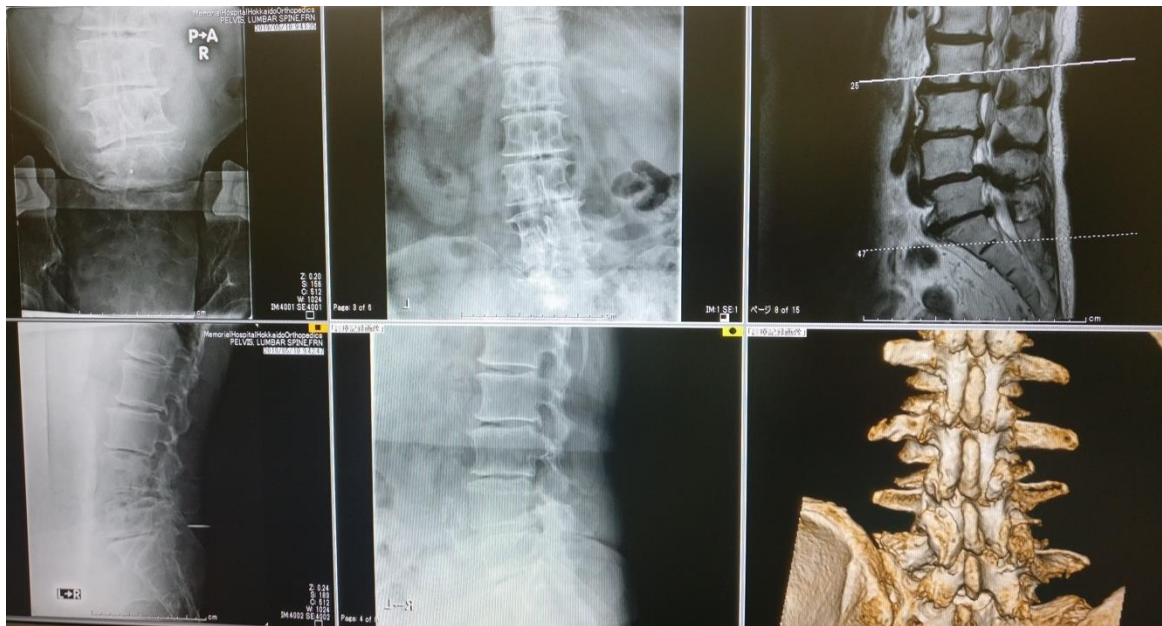


Post op xray

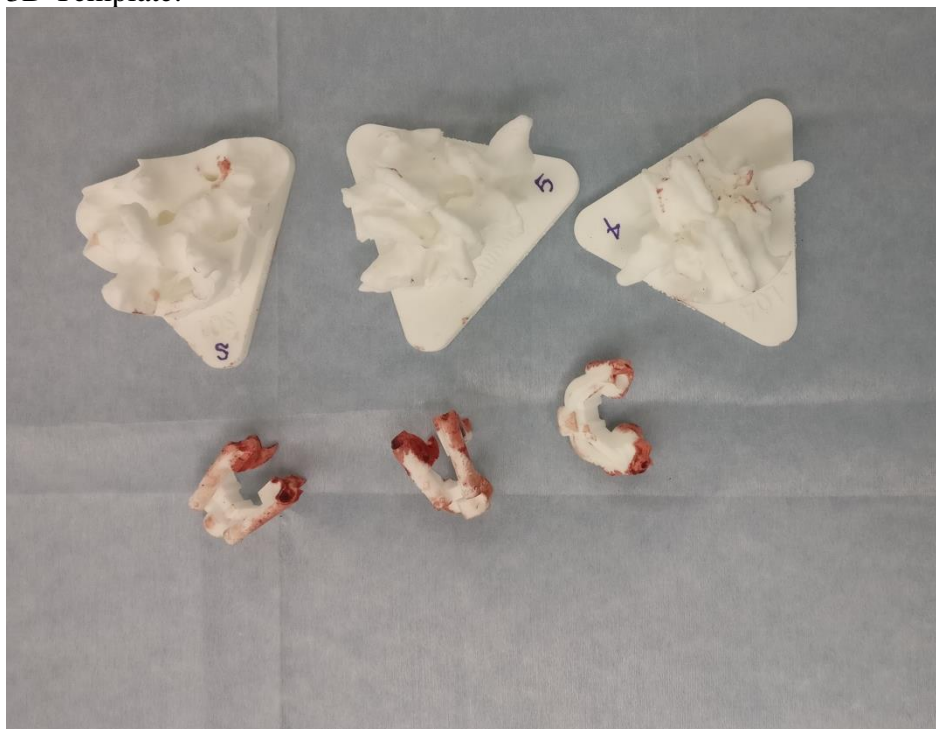




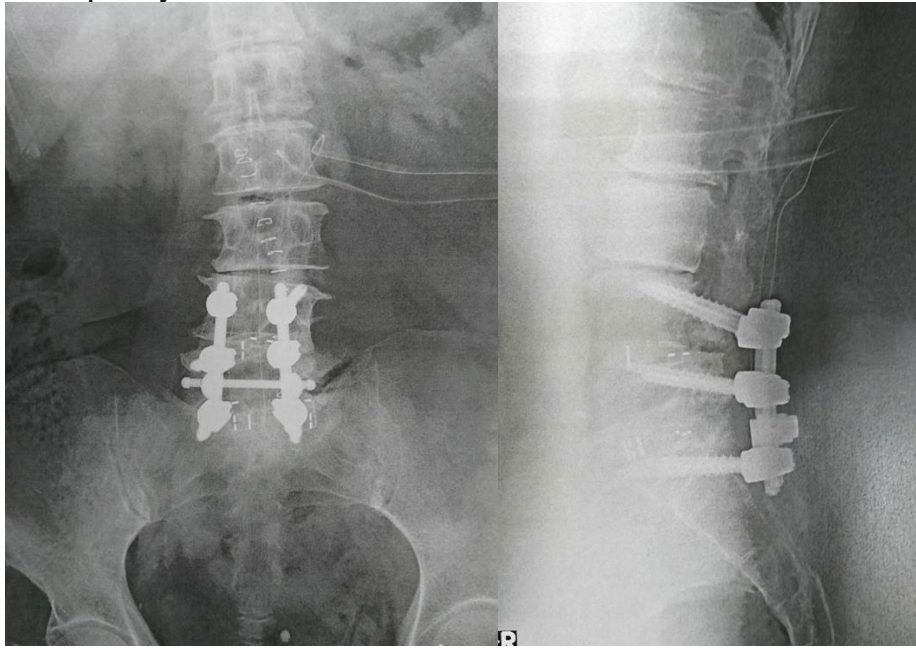
2) TLIF L4-S1 with cortical bone trajectory screws with Posterior decompression L2-L4 in a case of LCS with Degenerative Scoliosis



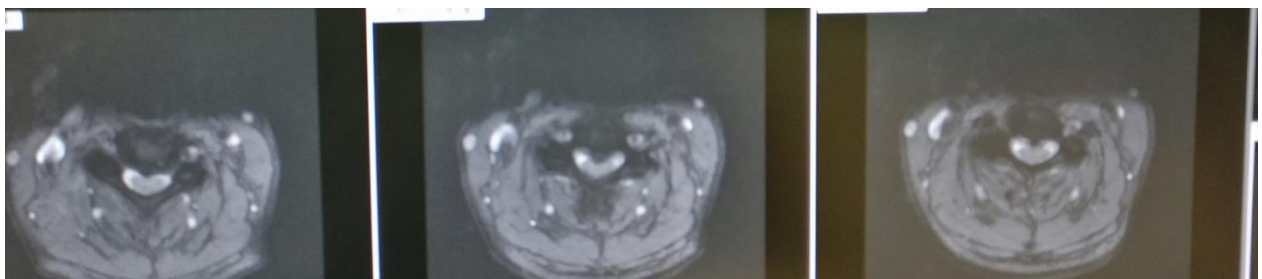
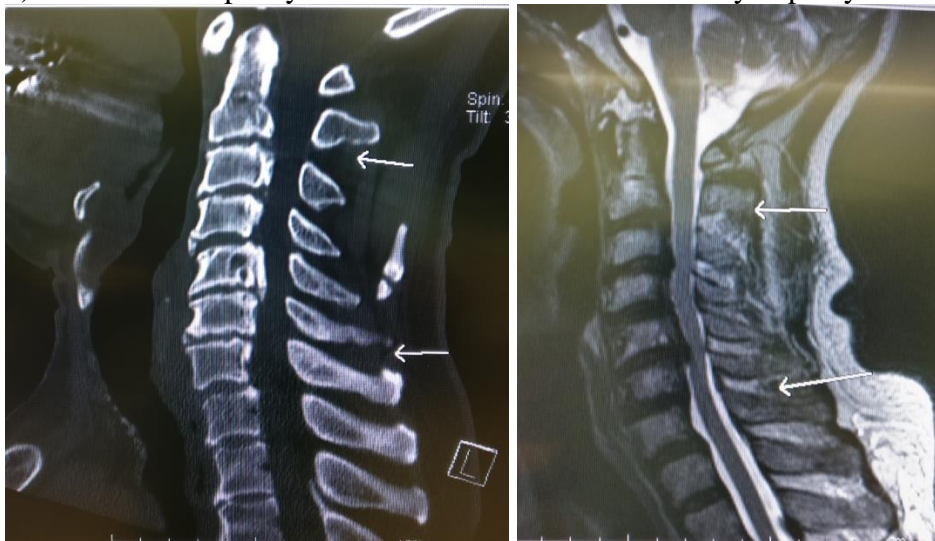
3D Template:

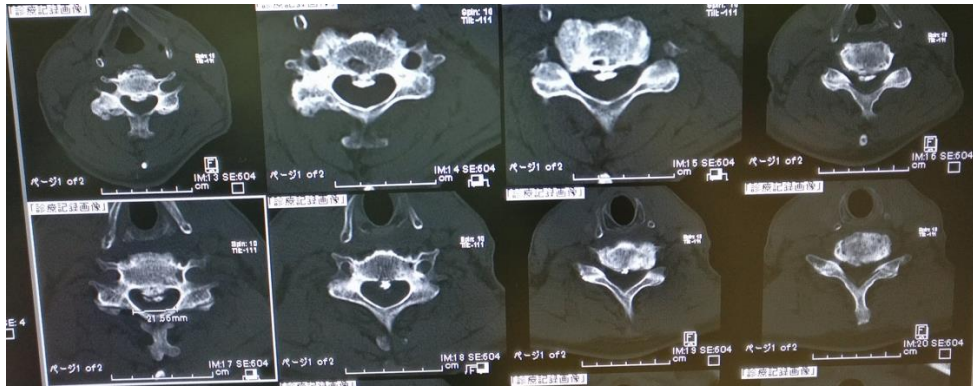


Post-op Xray

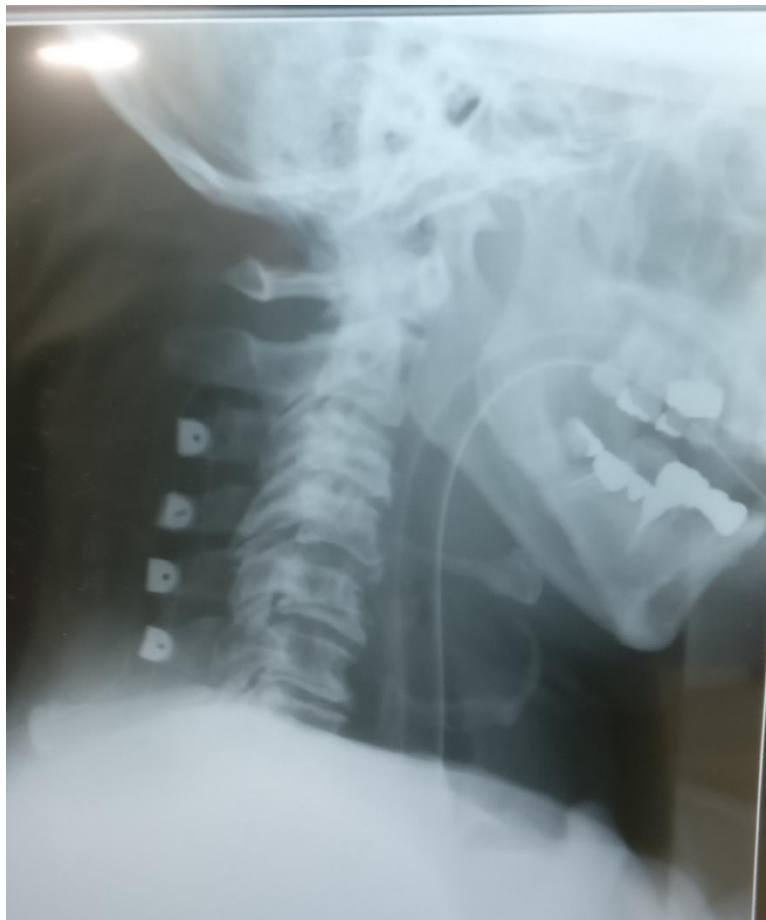

3) T saw Laminoplasty C3-C6 in a case of OPLL with myelopathy





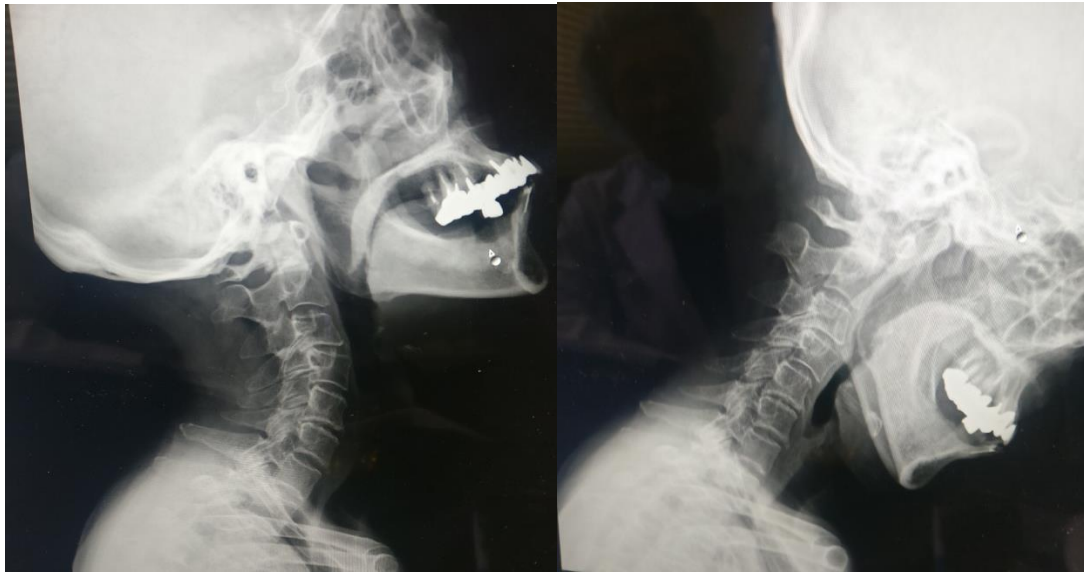
Post op Xray



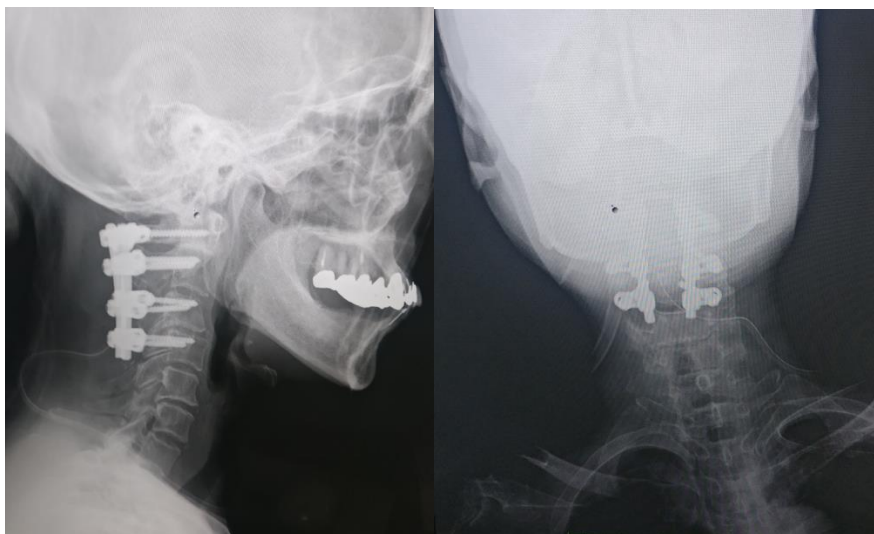
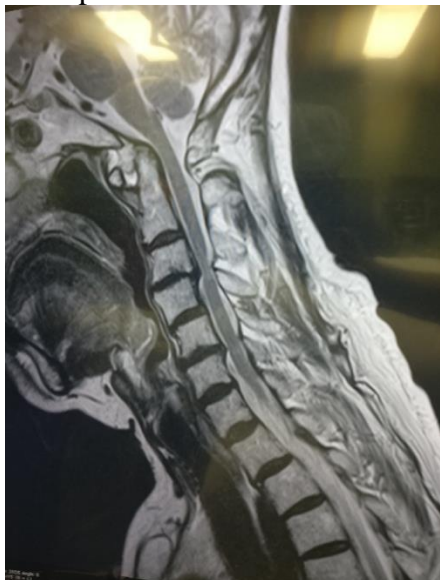
4) C1-C2 Subaxial instability in a case of Rheumatoid cervical Spine

Preop C1-C2 and Sub-axial instability X-ray





Pre Op MRI:





Dr Nirmal in Japan



Sapporo Orthopedic Hospital Team

To conclude, this was a very well organised and educational fellowship. Although 3 months is little to learn under Prof K. Abumi, it definitely has cleared many of my doubts and has made me a conceptually and technically smarter Spine surgeon. Lastly, I thank APSS for taking this initiative of organising fellowship programmes and supporting young surgeons. This will benefit many patients in the Asia Pacific region.