

REPORT FOR THE APSS – DEPUY SYNTHES SPINE CLINICAL FELLOWSHIP 2016

Fellow: **Dr. SHAH WALIULLAH**
MS, DNB, Dip. SICOT
Assistant Professor,
Department of Orthopaedic Surgery,
King George's Medical University, Lucknow, India.

Guide: **Dr. LORENZO ORSO OSTI**
MD, Ph.D (Ortho.)
Calvary Hospital, North Adelaide, Australia.

Duration: 13th March-2nd April (3 weeks)

Centre's Visited:

Calvary Hospital, Adelaide, Australia
Women & Children Hospital, Adelaide, Australia
St. Memorial Hospital, Adelaide, Australia.

I reached Adelaide on 13th March at 9 am morning after tiring journey of 16 hours but with high spirit. I was received by Mr Tim who dropped me at pre-booked apartment. He showed me nearby market from where I can take care of my daily need. My fellowship was supposed to begin on 14th March but due to local holiday at Australia, I was prior informed that there will be no clinical activity on 14th March Monday. I was free on Monday, so I requested Dr. Ted Mah that I am willing to meet him. To my surprise, he invited me on lunch at Jamie Olivier restaurant. On Monday afternoon, he took me to the restaurant. I will never forget, the wonderful lunch with him along with valuable guiding advices.

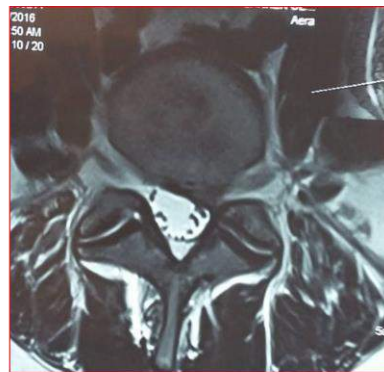
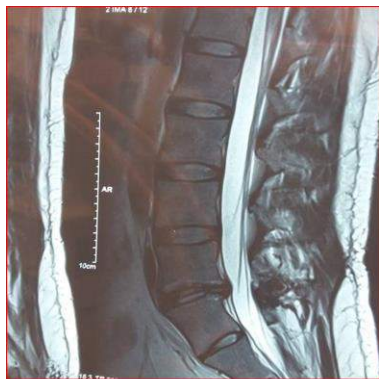
On Tuesday morning at 8 am my mentor Dr Orso Lorenzo Osti, picked me up from my room. He took me to the Calvary hospital. After formal introduction to staff, I went into operation theatre.



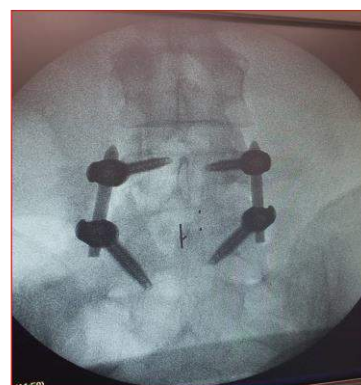
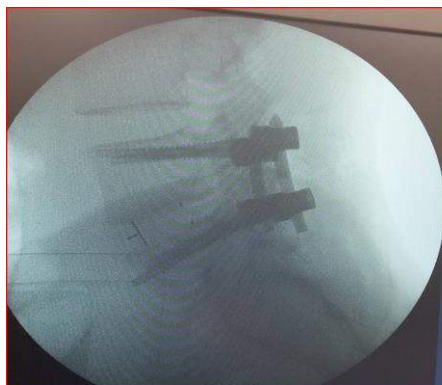
Calvary Hospital, Adelaide

My first case was 67 year old female who was suffering from chronic low back pain with radiculitis left side. Dr. Orso briefly discussed MRI and clinical finding of the patient. Patient was managed by laminectomy L4-L5 vertebrae. During operation he showed me facet hypertrophy causing compression over cord with narrowed foramen. He decompressed the cord efficiently. There was a small dent in duramator, he taught me how to manage CSF leak and dural tear. He stitched the dural defect by 4-0 vicryl, then he used Dura patch and fibrin glue to cover the defect.

My second case was 28 year old male who was suffering from chronic low back pain due to L5-S1 disc. Patient was managed by discectomy and total lumbar interbody fusion with incorporation of cage between L5-S1 disc space along with bone grafting. During operation he taught me new approach for exposure. He gave midline incision, after cutting skin and subcutaneous tissue, he incised fascia about one and half centimetre away from midline. He developed plane between muscles and reach up to transverse process then he did fluoroscopic pedicle screw fixation on one side followed by discectomy, cage insertion with bone graft and finally pedicle screw fixation on another side. There was only 80 ml blood loss after the whole surgery.

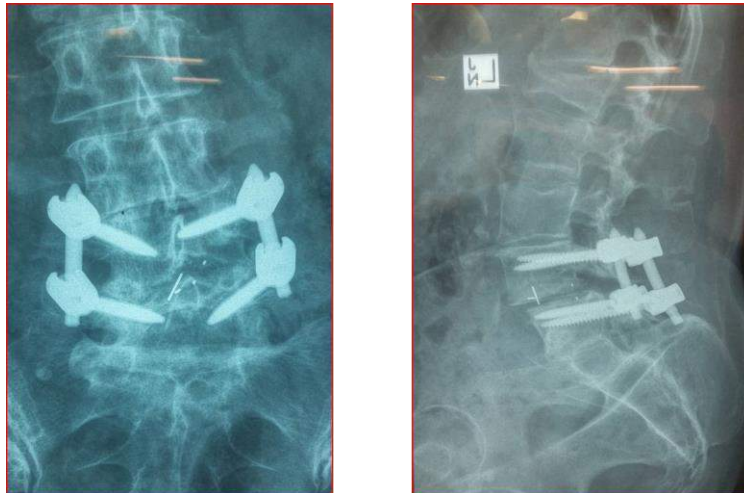


Pre-Operative MR scan



Intra-operative Fluoroscopic view

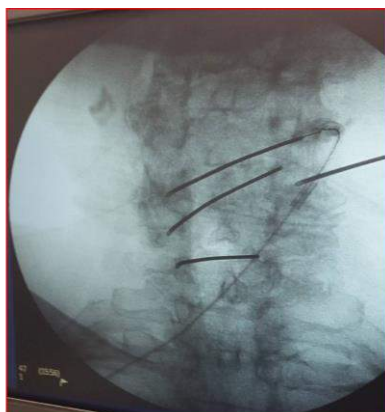
My third case was 69 year old female who was operated previously for L4-L5 listhesis two years back. Now patient had stiffness and back pain. Dr Orso briefly discussed her clinical and radiological finding. He showed me osteopenia around implant radiologically and per-operatively demonstrated loosened implant. He removed implant and did bone grafting with chronose mixed with bone marrow aspirate.



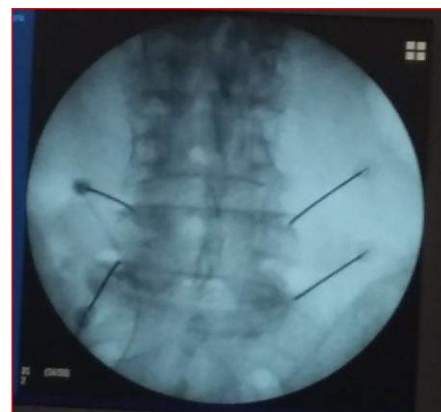
Pre-operative Radiograph

My fourth patient was 61 year old female who was operated previously for low back pain and managed by neuro modulation device. Patient got relieved from pain but due to motion battery got shifted superficially. Dr Orso explained me about neuro modulation device and its indication. He operated the patient and shifted the battery in deeper planes.

My fifth patient was 81 year old female suffering from cervical and lumbar spondylosis and was managed by Right and Left C4-C5, C5-C6, C6-C7 and Left L3-L4,L4-L5,L5-S1 Facet Rhizolysis by radio-frequency ablation.



Cervical Facetal Rhizolysis



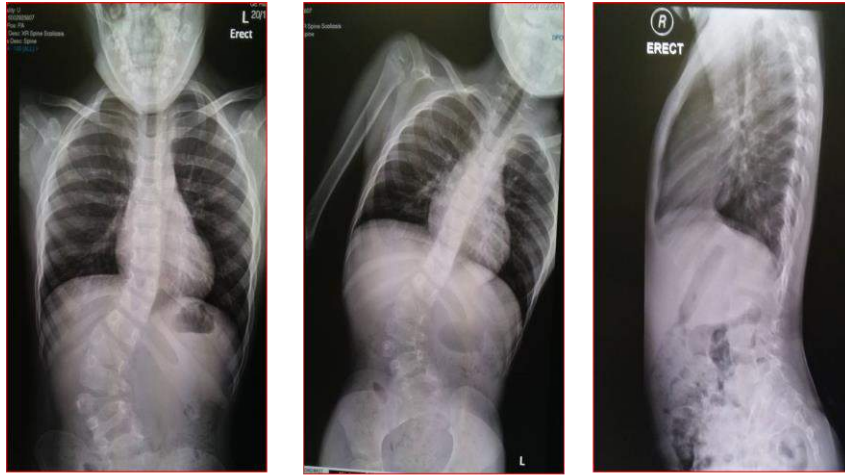
Lumber Facetal Rhizolysis

Next three patients with lumbar spondylosis were managed by radio-frequency ablation under local block and sedation. Radio-frequency ablation was done for 90 seconds at 90 degree Celsius.

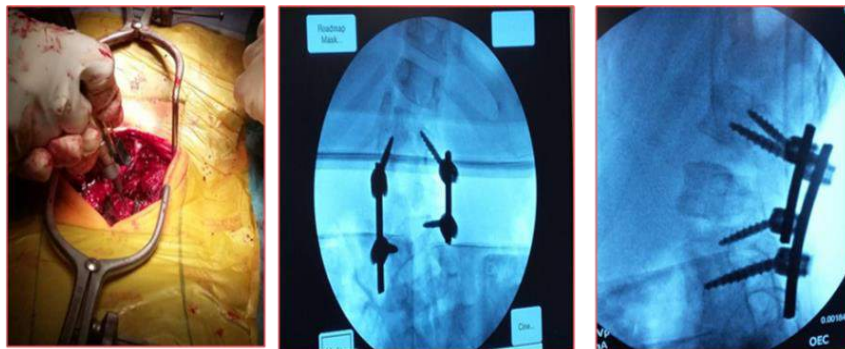
On 16th March morning I went to Calvary hospital on round with Dr. Orso to look after the yesterday operated patients. On round he taught me the protocol he follow, on his operative patient regarding nursing care, pain management and physiotherapy care. After round I went to Dr Orso's clinic to attend the outdoor patients. On every patient he taught me something new. The most important thing that I have learnt from him was effective communication and counselling. He was satisfying every question of patient to make them happy and feel better. After finishing out-door patients, we had a cup of tea. During this tea-time he taught me pedicle screw fixation on bone model.

On 17th March I went to Dr Orso private clinic to observe patients. Dr. Orso was very keen to taught me on every patient. I saw new patients as well as his follow-up patients. In new patients, he taught me clinical examination as well as MRI reading. After afternoon lunch, I went to spinal Clinic, Women's and Children Hospital, Adelaide. I met Dr. Nicoll William and Dr George, they escorted me toward their spinal clinic class room. In class room there was case on paediatric spinal deformity. Registrar presented the case then case was discussed in detail in terms of clinical findings, problem of patient, his investigation including Xrays, CT scan, MRI scan, planning of treatment and rehabilitation care. After case presentation, I again went to Dr. Orso's private clinic to observe further out door patients.

On 18th March morning, I went to operation theatre of Women's and Children Hospital, Adelaide. Today's case was 7 year old male child with scoliosis deformity. Patient had left sided scoliosis deformity with L3 hemi-vertebrae. Dr. Mike Selleby operated the case and he corrected deformity by excision of L3 hemi vertebrae, short segment stabilisation of L2 -L4 vertebrae with pedicle screw construct and bone grafting. He corrected scoliosis deformity from 65 degree to 20 degree. During this operation I observed neural monitoring and autologous blood transfusion technique.



Pre-Operative X-rays



Intra-operative clinical & Fluoroscopic view

In the evening, I was free. Dr. Orso invited me on evening dinner. At 6 pm, Dr. Orso took me from my apartment to his home. He introduced me with his family. I experienced a wonderful dinner with his family. His daughter prepared mushroom pasta, vegetarian salad, fruit brownie with icecream and other delicious stuffs. After having wonderful evening with Dr Orso, he dropped me at my room.

On 19th and 20th March, I was free, so I decided to explore Adelaide. On 19th March, I joined two other arthroplasty fellow from Royal Adelaide hospital. We went Adelaide zoo where we saw native animals of Australia. It was never before amazing experience to feed deer with your hands.

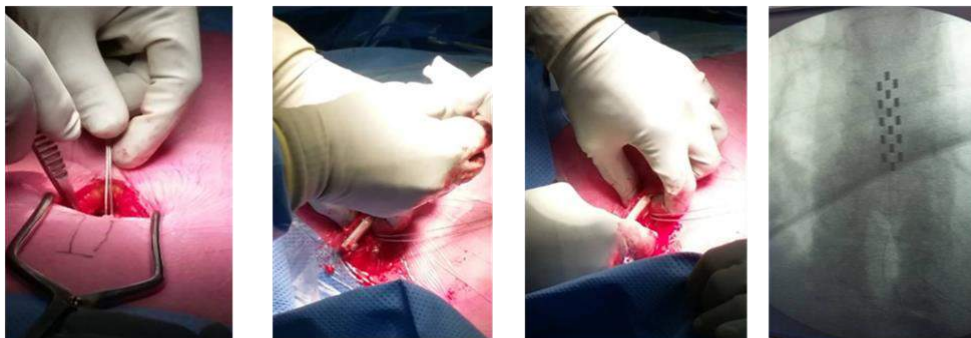
On 20th March in the afternoon, we went to Adelaide famous Glenelg beach where we enjoyed a lot. In the evening we took dinner at famous Nandos restaurant.

On 21st March I went to Dr. Orso's outdoor patient clinic. I observed more patients with degenerative spine. Dr. Orso discussed me in detail the clinical examination and radiological findings of few patients. Whole day, I learnt so many things from Dr. Orso. After out-door patient clinic we had tea, than we discussed next day O.T. list.

On 22nd March, I went to Calvary hospital OT. My first case was 66 years old female suffering from Lumber canal stenosis with lumber spondylosis. Dr. Orso did central laminectomy of L3-L4/L4-L5 and performed decompression along with segmental pedicle screw fixation with bone grafting.

Second patient was 64 year old male who was operated previously for low back pain and managed by dorsal column neuro modulation device. Patient got relieved from pain but due to motion battery got shifted in buttock and causing trouble in sitting. He operated the patient and shifted the battery superiorly.

Third patient was 63 year old female who was suffering from Chronic neuropathic pain following previous spinal surgery. Patient was managed by implantation of dorsal column neuro-stimulation device. It was my first exposure to neuro modulation devices. Dr. Orso showed me implantation by performing laminotomy at T12 level than he introduced the electrodes and placed at T9-T12 level. Battery was placed by another incision at left illiac crest level.

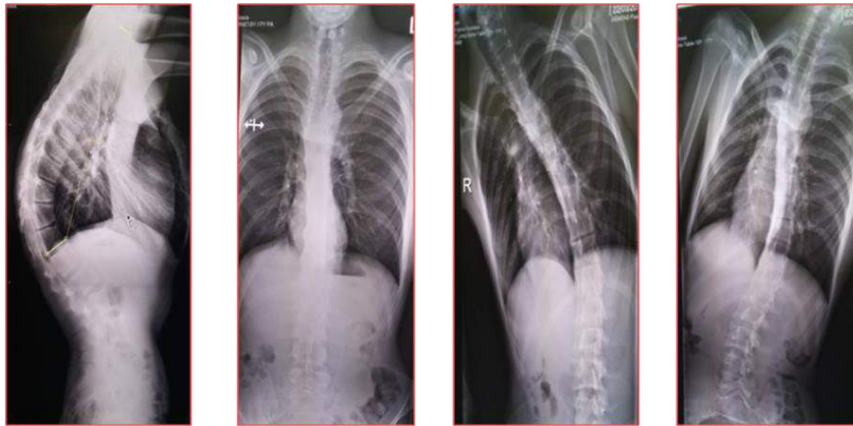

Intra-operative clinical & Flourosopic view

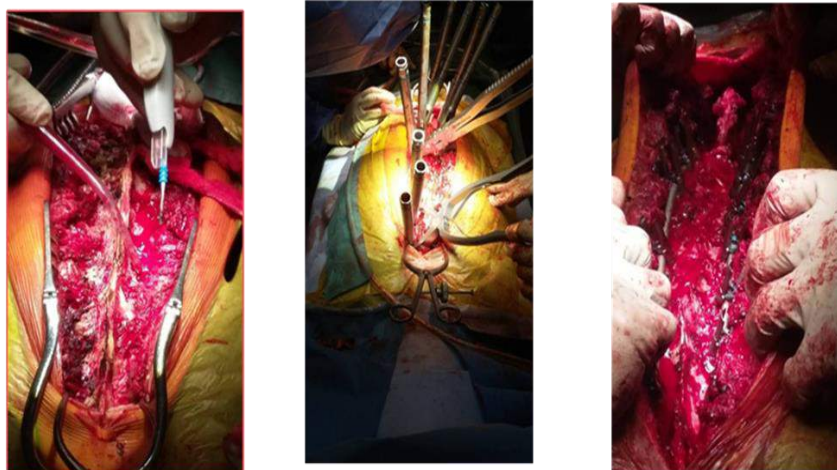
Next four patients were managed by facet joint Rhizolysis under flourosopic guidance with local block and sedation. Dr Orso taught me the exact location for Rhizolysis in cervical and Lumber spine. Radio-frequency ablation was done as a day care procedure.

On 23rd March morning, I went to operation theatre of Women and Children hospital. We have case of 15 year old male having kyphotic deformity of around 85 degree with apex in mid thoracic region. Midline vertical incision was given from upper thoracic region to

lower lumbar region. After meticulous dissection, Dr Brian Freeman taught me about blind technique of pedicle screw fixation. Deformity was correct by cantilever mechanism under neural monitoring. Deformity was successfully corrected along with fusion. In the end Dr. Brian shared me the post operative protocol for their deformity correction patients.



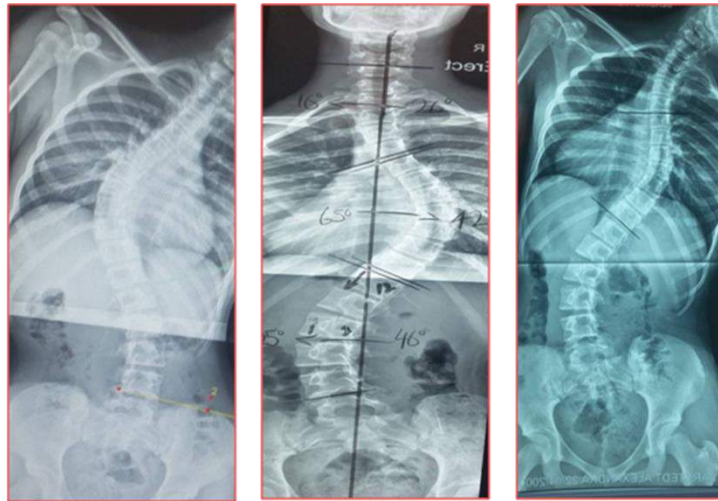
Pre-operative radio-graph films



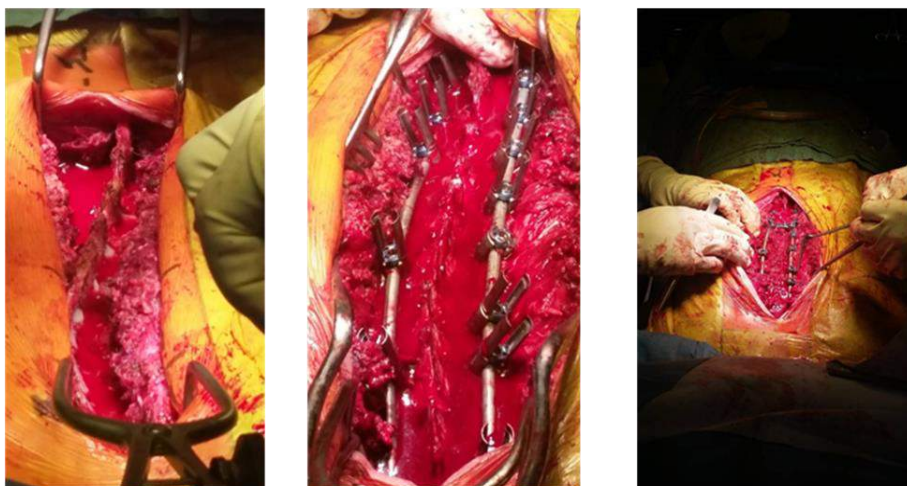Intra-operative clinical view

On 24th morning, I went with Dr. Orso to Calvary hospital to observe his post operative patients. He discharged two of his patients after observing satisfactory progress. After having tea with him, we went back to his out-patient clinic. I observe out-door patients. At 1am, after lunch time I went to operation theatre of St Memorial Hospital where we have 15 year old female with adolescent idiopathic scoliosis. Prof Peter Cundy explain me the radiological findings of the patient. He did posterior instrumentation from T4 to L2 with free

hand blind technique. He used Expedium VERSE Alpha System for correction of deformity. He corrected primary curve from 45 degree to 10 degree very efficiently. I was suprised with zeal and dedication of Prof Cundy, he did everything from patient positioning to operation notes by his own. He explained all my queries in a very lucid way.



Pre-operative radio-graph films



Intra-operative clinical view

From 25th March onwards, there was happy Easter weekend holidays. On 26th March, I visited Cleland National Park where I saw Kangaroos, Koalas and other animals very closely. On 28th March, I arrived to Melboune to attend APOA Congress.



I would like to thank Asia Pacific Spine Society for providing me for APSS Depuy Synthes Spine Clinical Fellowship. This fellowship paved a new zeal in me to explore degenerative spine. I am really grateful to Dr. Kuniyoshi Abumi (Chairman), Dr. Mun-Keong Kwan (Honorary Secretary), Dr. Chris Chan for considering me for valuable fellowship. I am also thankful to Prof. Arvind Jayasawal and Prof. HKT Raza for guiding me and acting as a constant source of inspiration to me. The fellowship was very well organised and planned, the whole kudos goes to Ms. Jenny Wong who helped me throughout my fellowship.

LOG BOOK

S. No	Date	Day	Age	Sex	Diagnosis	Procedure	Surgeon	Hospital
1.	15-03-16	Tuesday	67	F	Radicular pain left leg	L4-L5 Laminectomy	Dr Orso	Calvary Hospital
2.	15-03-16	Tuesday	28	M	Lumber canal stenosis	TLIFF	Dr Orso	Calvary Hospital
3.	15-03-16	Tuesday	69	F	Loosening of implant	Removal of Implant and Bone Grafting	Dr Orso	Calvary Hospital
4.	15-03-16	Tuesday	61	F	Painful battery site of neurostimulator machine	Repositioning of Battery	Dr Orso	Calvary Hospital
5.	15-03-16	Tuesday	81	F	Cervical Spondylosis with lumber canal stenosis	Right and Left C4-C5,C5-C6, C6-C7 and Left L3-L4,L4-L5,L5-S1 Facet Rhizolysis	Dr Orso	Calvary Hospital
6.	15-03-16	Tuesday	55	M	Lumber spondylosis	Right and Left L4-L5,L5-S1 Facet Rhizolysis	Dr Orso	Calvary Hospital
7.	15-03-16	Tuesday	82	M	Lumber spondylosis	Right and Left L3-L4,L4-L5,L5-S1 Facet Rhizolysis	Dr Orso	Calvary Hospital
8.	15-03-16	Tuesday	56	F	Lumber spondylosis	Right L4-L5,L5-S1 Facet Rhizolysis	Dr Orso	Calvary Hospital
9.	18-03-16	Friday	7	M	Left sided Scoliosis	Excision of L3 hemi vertebrae, short segment stabilisation of L2 -L4 vertebrae with pedicle screw construct and bone grafting	Dr. Mike Sellby	Women & Children Hospital
10.	22-03-16	Tuesday	66	F	Lumber canal stenosis with lumber spondylosis	L3-L4/L4-L5 decompression Laminectomy with segmental pedicle screw fixation with bone grafting	Dr Orso	Calvary Hospital
11.	22-03-16	Tuesday	64	M	Painful site of neurostimulator battery	Repositioning of neurostimulator	Dr Orso	Calvary Hospital
12.	22-03-16	Tuesday	63	F	Chronic neuropathic pain following spinal surgery	Definitive implantation of dorsal column neurostimulator	Dr Orso	Calvary Hospital
13.	22-03-16	Tuesday	74	F	Lumber spondylosis	Right and Left L4-L5,L5-S1 Facet Rhizolysis	Dr Orso	Calvary Hospital
14.	22-03-16	Tuesday	55	F	Cervical spondylosis with lumber canal stenosis	Right and Left C3-C4,C4-C5, Right and Left L4-L5,L5-S1 Facet Rhizolysis	Dr Orso	Calvary Hospital
15.	22-03-16	Tuesday	81	M	Lumber canal Srenosis	Right and Left L3-L4,L4-L5,L5-S1 Facet Rhizolysis	Dr Orso	Calvary Hospital
16.	22-03-16	Tuesday	54	F	Lumber spondylosis	Right and Left L4-L5,L5-S1 Facet Rhizolysis	Dr Orso	Calvary Hospital
17.	23-04-16	Wednesday	15	M	Marfan syndrome Kyphosis	Correction of kyphotic deformity by posterior instrumentation and fusion from T4 -L3 with Expedium VERSE Alpha System	Prof Brian Freeman	Women and Children Hospital, Adelaide
18.	24-04-16	Friday	15	F	Adolescent Idiopathic Scoliosis	Posterior instrumentation and fusion from T4 -L2 with Expedium VERSE Alpha System	Prof Peter Cundy	St. Memorial Hospital, Adelaide

PROPOSED WEEKLY WORK SCHEDULE

DR SHAH WALIULLAH

13 March to 28 March 2016

<i>Monday</i>	<i>Tuesday</i>	<i>Wednesday</i>	<i>Thursday</i>	<i>Friday</i>
AM FREE	8.30am – Dr Osti, Calvary Hospital, North Adelaide Operating (89 Strangways Tce, North Adelaide 0882399100)	9am – Assoc. Professor Peter Cundy Women’s & Children’s Hospital (King William Street, Adelaide) Operating	9am Dr Osti, Calvary Ward Round 10am – Dr Osti’s Rooms, Private Outpatients	9am – Assoc. Professor Peter Cundy Women’s & Children’s Public Spinal Outpatients
PM 1pm – Dr Osti’s Rooms Private Outpatients (12 Walter Street, North Adelaide, 0882391889)	Dr Osti, Operating	Assoc. Professor Peter Cundy Women’s & Children’s Hospital Operating	12.30-1.30pm Lunchtime Meeting Women’s & Children’s Hospital Paediatric Orthopaedics	FREE