



## The Report of Clinical Fellowship Program



**UNIVERSITI MALAYA**

**Akira Iwata**


HOKKAIDO UNIVERSITY, HOKKAIDO, JAPAN  
DEPARTMENT of ORTHOPEDIC SURGERY

**Asia Pacific Spine Society (APSS) –Depuy Synthes Spine Clinical Fellowship 2017 took place from 31<sup>st</sup> Aug to 21<sup>st</sup> Sep 2017.**

### **1. Introduction**

I am Dr. Akira Iwata graduated from Hokkaido University Graduate School of Medicine. I have contributed to the regional work at Hokkaido University Hospital as a spine surgeon. I recently handle scoliosis and spinal tumor cases. However, I had little experience for severe scoliosis cases.

I am grateful that APSS had arranged me to be attached to the Orthopaedics Surgery at Malaya University. I saw once Prof Kwan and Prof Chris conducted the live surgery for the correction of scoliosis. I was excited when I got the information of the acceptance for this fellowship at Malaya University.



The day I reached Malaysia was a national holiday. However, Prof Kwan, Prof Chris and Dr. Chiu gathered for waiting for the lunch with me. They give me plenty of information about “how to enjoy in Malaysia”. They probably know that anxieties come from a lack of information. I was very comfortable about their warmhearted mind.

## **2. Contents of fellowship**

The Orthopaedic Spine Unit of University Malaya has been a pioneer in provision of surgical spine services for various complex spine afflictions in Malaysia. Being one of the first center in the nation as well as in this region, they have taken the initiative to continue the legacy in providing the quality clinical services, continuous education and learning as well excellence in research and publication. With daily inpatients averaging 15 to 20 patients, outpatient consultations of over 500 patients per month and annual operative approximately 400-500 cases, this center has one of the highest volume of spinal patient care in the Malaysia. Of note, their spine unit offers surgery for complex spinal deformities and is also a leader in minimally invasive stabilization techniques in spinal oncology surgery in the Asian region.

In the Malaya University Hospital, Surgeries for the correction of scoliosis are treated 160 cases per year. I saw that they treated 5 patients in 24 hours with a total of 500 degree Cobb angle. It was a great opportunity to learn how to consider and handle scoliosis.



Through the surgery to correct the scoliosis, I could learn the concept of “letting the spine go”. We have been taught that we should correct the spine as much as possible without deep consideration about the rigidity in uninstrumented segments. Probably mentors know the problems through the plenty of scoliosis cases. “Neck tile” is one of the representative problems to care about after correction of scoliosis.



The techniques of the correction for scoliosis were splendid. It was so short time to get the anchors using pedicle screws correctly and to finish the correction of scoliosis by dual attending surgeons. Even in the cases of so narrow pedicles, they could insert using extra-pedicular screw placement technique.

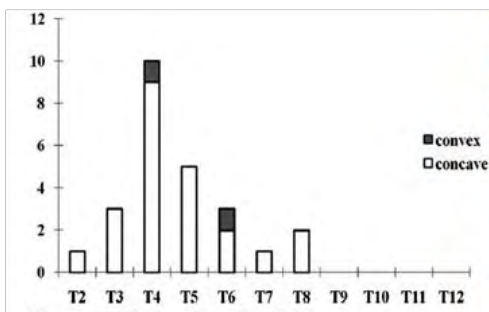
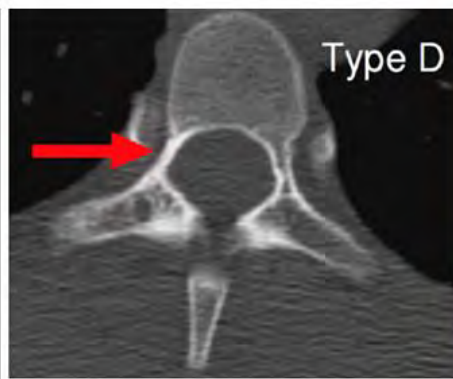



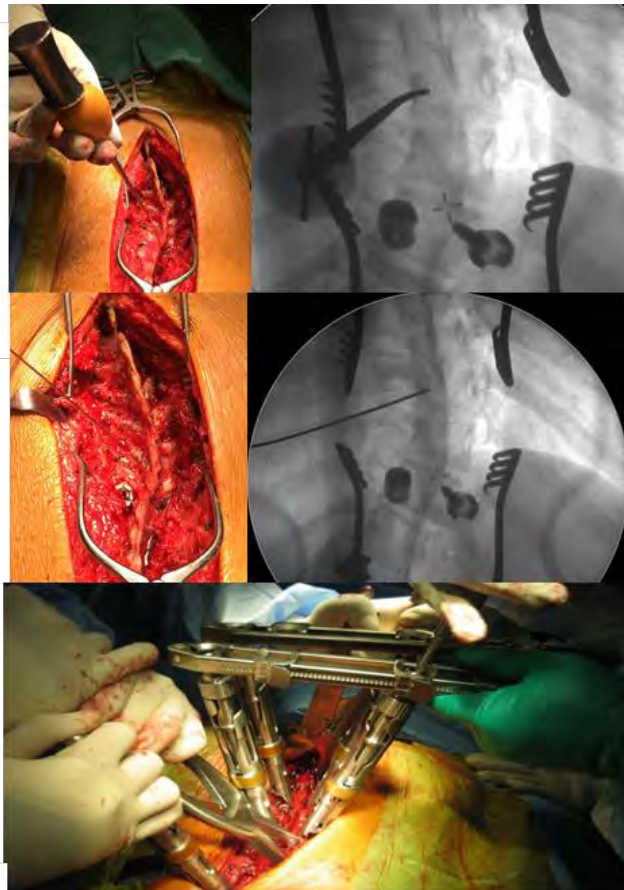
Figure 5. Distribution of type D pedicles.



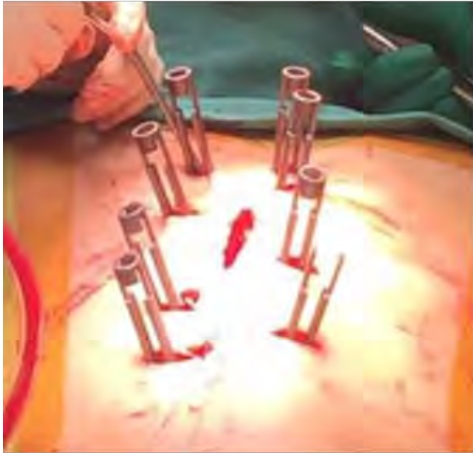Cortical channel < 2mm



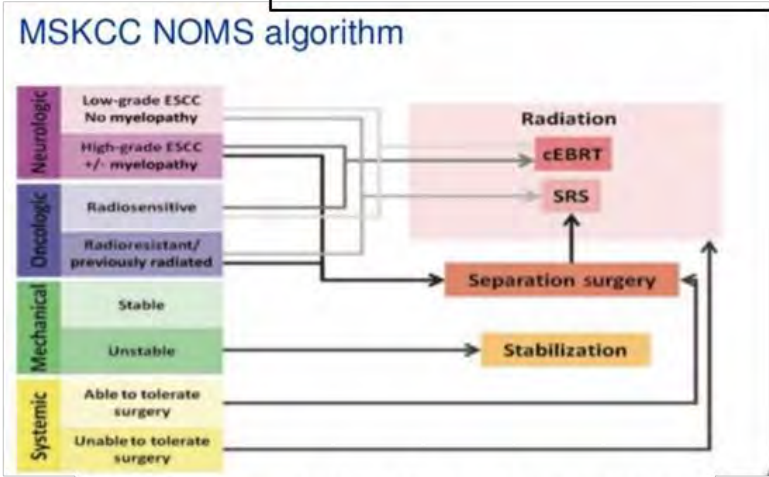
Funny rod for convex side



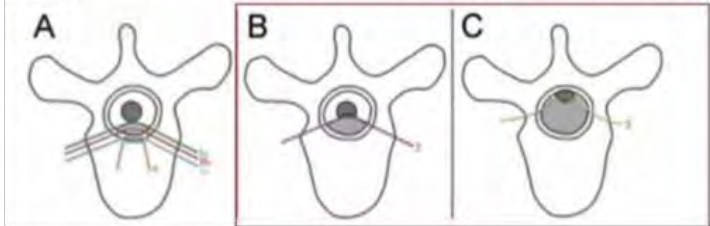
I also had the opportunity to learn how to handle patients of spinal metastases with paraplegia. They told the patient's families about the selections of treatment politely. The explanation was quite easy to understand, and the families could select the treatment considering the prognosis. After embolization, circumferential decompression with mini-incision and fixation percutaneously were conducted. Their techniques were careful and accurate with little bleeding.



After embolization,  
Circumference  
decompression  
 through mini incision  
 and PPS for SBRT

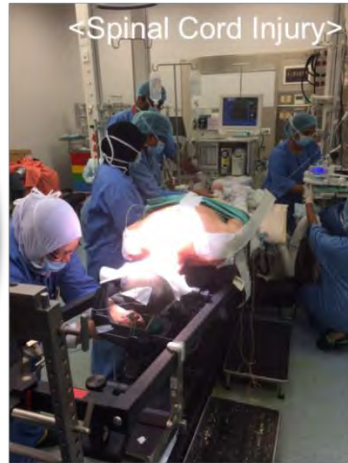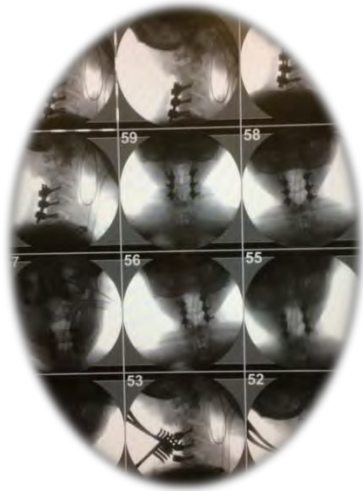


Laufer et al. the Oncologist 2013

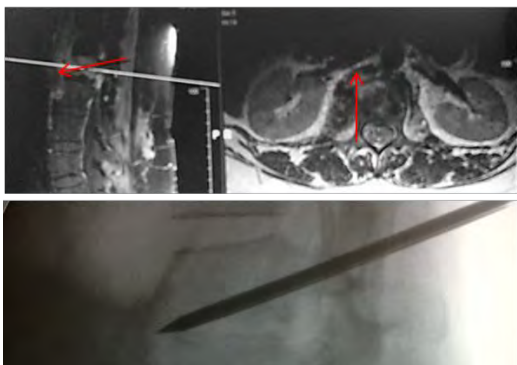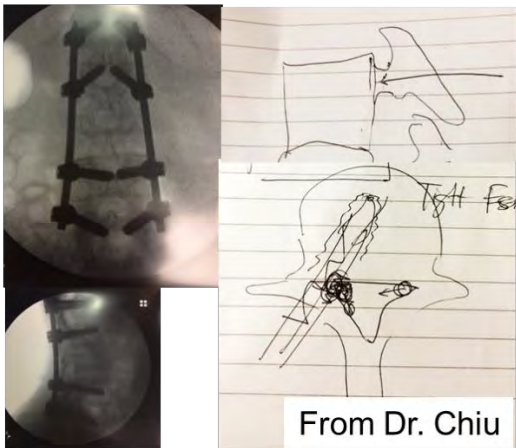


Bilsky et al J Neurosurg Spine 2010

Infections and injuries are main treatment target for the spine surgeons in all over the world. Percutaneous techniques were often introduced considering the less invasiveness.



Spinal disorders needed long hospitalization;	
TB spine	; 3 Patients
Spondylodiscitis	; 14 Patients
Spinal Cord Injury	; 2 Patients
Spinal Metastases	; 3 Patients

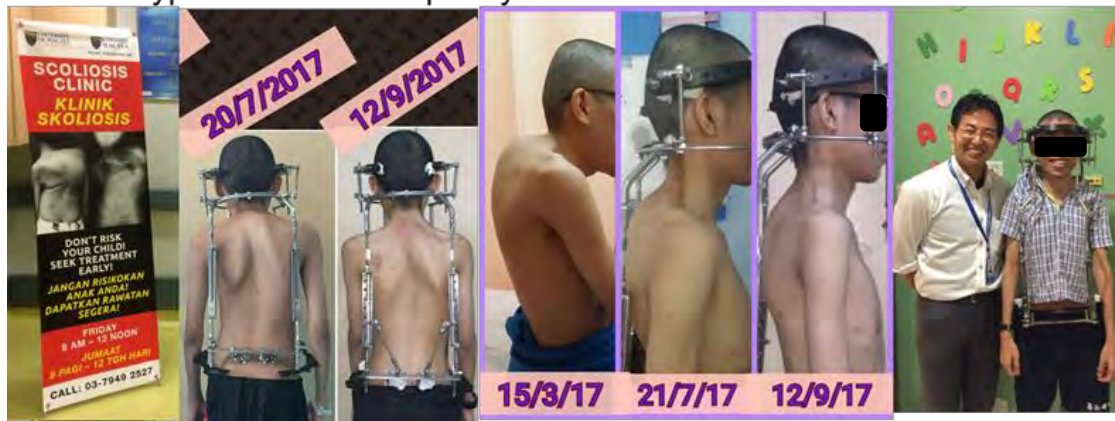

My fellowship schedule was organized very well. I experienced a lot in the ward round, teaching activities, and outpatient clinic as one of a spine resident doctor.

Time	Monday		Tuesday		Wednesday		Thursday	Friday	Saturday	Sunday or PH
7.15am to 8am	MO's Presentation	Research meeting	Pre-op presentation		MO's Presentation Journal presentation	Research meeting	Pre-op presentation	Ward round	UMSC OT (8am to 5pm)	Rest day
8am to 9am	MOs join research meeting or attend M&M meeting once a month		Elective OT	Long case teaching	MOs join research meeting		Elective OT	Long case teaching		
9am to 2pm	Grand ward round			Spine clinic		Scoliosis clinic				
2pm to 5pm	Pre-op assessment	Short case teaching fortnightly		Pre-op assessment		Personal research time				
5pm to 10pm	UMSC OT		UMSC OT		UMSC OT					
*Scheduled On-call MO & lecturer stand by for any emergency referral & spine operation 24 hours/day & 7 days/week *Scheduled On-call MO does ward round daily 9am-12pm										

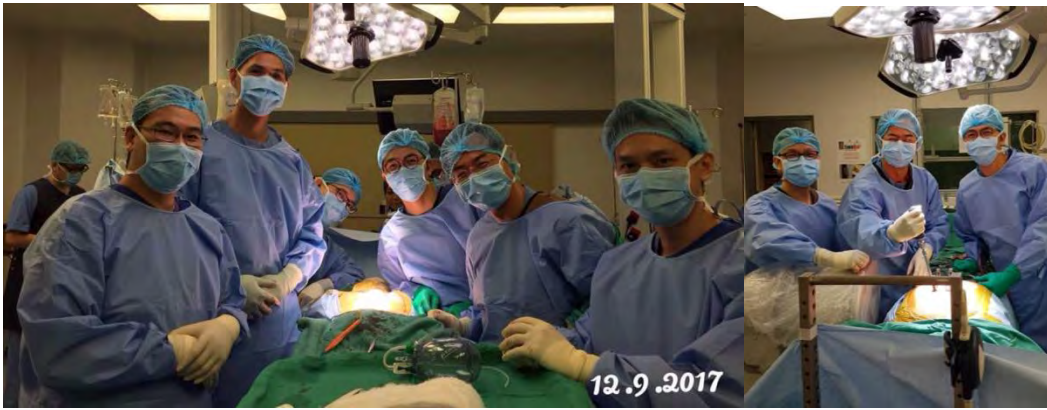MO: Medical officer  
 OT: Operation theatre  
 UMSC: UM Specialist Centre  
 M&M: Morbidity & Mortality  
 PH: Public Holiday

### <Kyphoscoliosis with paralysis due to neurofibromatosis>



I could know that spine residents were trying to struggle with difficult cases optimistically. The education systems were splendid for the spine residents.





**3. Conclusion**

This 3 weeks fellowship program was quite stimulating for me. Through this program, I learned splendid concepts and techniques for the correction of scoliosis. Moreover, I was impressed that deep consideration for the recovery of patients makes clinical work, education, and research work to proceed cooperatively. I would like to show my deepest gratitude to Prof. Kwan Mun Keong, Prof. Chris Chan Yin Wei, and Dr. Chiu Chee Kidd. Mrs Jenny Wong had been trying to coordinate in the best possible way for me. I would like to thank Asia Pacific Spine Society (APSS).



**Logbook: Operations attended during this fellowship**

<b>Cas e</b>	<b>Gender</b>	<b>Age</b>	<b>Disease</b>	<b>Level, degree</b>	<b>Operation</b>
1	F	46	Spinal metastases	T10	Circumpherantial decompression+MISt (Fixation)
2	F	13	Congenital scoliosis	L2 hemivertebra+L5 tilt(pelvic obliquity, lumbo-sacral junction curve)	T10-L5 correction from posterior
3	F	23	L2 burst fracture (AO A4)	L2	percutaneous fixation L1-L3
4	F	56	TB	L1	biopsy through L1 pedicle to L1/2 disc and psu in psoas
5	F	73	L1,L2 osteoporotic vertebral fracture	L1 and L2	Vertebroplasty×2
6	M	77	Cervical spondylo myelopathy	C3-6	C3-5 laminectomy+C2,C6 partial alaminectomy+C3-5 fusion
7	M	42	L5/S hernia	L5/S	discketomy assisted with microscope
8	F	18	post-op verst fracture	L-S	implant removal L3-S1
9	F	53	L4/5 hernia	L4/5	laminoplasty&herniotomy
10	M	73	Spinal metastases (lung Ca s/o)	T8	Circumpherantial decompression+ MISt (Fixation; T5-10)
11	F	13	AIS Lenke type 1BN	T3-L1	Posterior correction and fusion (T3-L1)

12	F	13	AIS Lenke type 5B-	T9-L3	Posterior correction and fusion (T9-L3)
13	M	60	spinal tumor (multiple myeloma s/o)	T9	Circumpherantial decompression+ Fixation; T8-10
14	M	63	TB spine	L3 collapse	MISt (L1-L5 posterior fixation)
15	F	12	AIS Lenke type 1B-	T3-L1	Posterior correction and fusion (T3-L1)
16	M	23	L5/S hernia	L5/S	Laminoplasty + herniotomy
17	M	6	Symptomatic Scoliosis (Russell-Silver synd.)	Double majour curve	glowing rod elongation (Lumbar)
18	M	13	Symptomatic Scoliosis (Prader-Willi synd.)	Major thoracic curve	glowing rod elongation (thoracolumbar)
19	M	43	L4/5 hernia	L4/5 (Rt.)	Posterior decompression (under Microscope)
20	M	23	C4/5 fracture dislocation (Vertical compression stage 3) (Epilepsy)	C4/5	C3-5 posterior fusion (lateral mass screw)+C4/5 decompression
21	M	16	AIS Lenke type 2A-	T3-L2	Posterior correction and fusion (T3-L2)
22			L5/S hernia	L5/S	laminoplasty and herniotomy